

TRABECULAR METAL[®] IMPLANT CLINICAL COMPENDIUM

BioBoost Effect[®]: The Results

Author

Elnaz Ajami, MSc, PhD

Hai Bo Wen, PhD



Table of Contents

| | |
|--|----|
| Introduction | 4 |
| Rapid Recovery Studies: Two-Week Final Loading | 5 |
| Immediate Loading Of Trabecular Metal Enhanced Titanium Dental Implants: Interim Results From An International Proof Of Principle Study. ^{1, 2, 3} | 5 |
| Immediate Implant Loading: A Comparison Of Trabecular Metal And Tapered Screw-Vent [®] Dental Implants. ⁴ | 6 |
| Immediate Loading Of Tantalum-Based Implants In Fresh Extraction Sockets: Long-Term Outcomes. ⁵⁻⁷ | 7 |
| Rapid Recovery Studies: Immediate Placement | 8 |
| Immediate Placement Of A Porous-Tantalum, Trabecular Metal-Enhanced Titanium Dental Implant With Demineralized Bone Matrix Into A Socket With Deficient Buccal Bone: A Clinical Report. ⁸ | 8 |
| The Influence Of Implant Design On Primary Implant Stability Simulating Immediate Placement Conditions Of The Anterior Maxilla. ⁹ | 9 |
| Rapid Recovery Studies: The BioBoost Effect | 10 |
| A Trabecular Metal Implant 4 Months After Placement: Clinical-Histologic Case Report. ¹⁰ | 10 |
| Osseoincorporation Of Porous Tantalum Trabecular-Structured Metal: A Histologic And Histomorphometric Study In Humans. ¹¹ | 11 |
| Comparing Initial Wound Healing and Osteogenesis of Porous Tantalum Trabecular Metal and Titanium Alloy Materials. ¹² | 12 |
| New Bone Formation And Trabecular Bone Microarchitecture Of Highly Porous Tantalum Compared To Titanium Implant Threads: A Pilot Canine Study. ¹³ | 14 |
| Porous Tantalum Increases Interfacial Bone Tissue Mineralization Compared To Titanium Threaded Section Of Implants. ¹⁴ | 15 |
| Biomechanical Analysis And Osteogenic Gene Expression On Porous Tantalum Implants Placed In A Gap Healing Model. ^{15, 16} | 16 |
| Risk Management Studies: Poor Quality Bone | 18 |
| Grafted Sites And Large Defects | |
| Rehabilitation Of Extremely Atrophic Maxillae With Mineralized Allograft And Highly Porous Dental Implants. ¹⁷ | 18 |
| Retrospective Analysis Of Porous Tantalum Trabecular Metal-Enhanced Titanium Dental Implants. ¹⁸ | 19 |
| Bone Modifications Around Trabecular Metal Implants Inserted Without Primary Stability. A Case Series With 3 Years Follow Up. ^{19, 20} | 20 |
| A Novel Approach For The Coronal Advancement Of The Buccal Flap. ²¹ | 21 |
| Risk Management Studies: Impaired Healing | 22 |
| Elevated Risk In Routine Practice | |
| Prospective, Multicenter Evaluation Of Trabecular Metal-Enhanced Titanium Dental Implants Placed In Routine Dental Practices: 4-Year Report. ^{22, 23} | 22 |

| | |
|--|----|
| Postablative Cancer | |
| Evaluation Of Highly Porous Dental Implants In Postablative Oral And Maxillofacial Cancer Patients: A Prospective Pilot Clinical Case Series Report. ²⁴ | 23 |
| Systemic Disease: Patient Outcomes | |
| Immediate Loading Of Tantalum-Based Implants In Patients With Systemic Diseases. Clinical And Radiographic Long-Term Outcomes. ²⁵ | 24 |
| Immediate Loading Of Tantalum-Based Implants In Fresh Extraction Sockets In Patient With Sjogren Syndrome: A Case Report And Literature Review. ²⁶ | 26 |
| Systemic Disease: The Bioboost Effect | |
| Transcriptomic Analysis Of Wound Healing Around Tantalum And Titanium In Diabetes. ²⁷ | 27 |
| Transcriptomic Profiling Of Tantalum Metal Implant Osseointegration In Osteopenic Patients. ²⁸ | 28 |
| Prior Infection | |
| Immediate Loading Of Trabecular Tantalum-Based Implants Placed In Infected Sites With Full Ceramic Restorations. One Year Clinical Evaluation. ²⁹ | 29 |
| A Retrospective Survival Study Of Trabecular Tantalum Implants Immediately Placed In Posterior Extraction Sockets Using A Flapless Technique. ³⁰ | 30 |
| Evaluation Of Different Implant Designs In A Ligature-Induced Peri-Implantitis Model: A Canine Study. ³¹ | 31 |
| Revision Therapy Studies and Cases | 32 |
| Replacement Of Failed Implants | |
| Immediate Placement Of Trabecular Metal Implants In Sites of Failed Implants. ³² | 32 |
| Revision Of Peri-Implantitis-Related Failure With Trabecular Metal Implant: 6-Year Follow-Up..... | 33 |
| Revision Of Failed Implant With Guided Bone Regeneration And Trabecular Metal Implant: 3-Year Follow-Up..... | 34 |
| Immediate Revision With Puros® Allograft-Stabilized Trabecular Metal Implant: 5-Year Follow-Up..... | 36 |
| Additional Publications | 37 |
| References | 38 |

Notes to clinicians on the use of ZimVie Dental Products: Before using a ZimVie Dental product, the operating surgeon/practitioner in charge should carefully study the indications, contraindications, recommendations, warnings and instructions, as well as all other product-specific information (technical product description, description of the surgical and restorative technique, catalogue, etc.) and fully comply with them. Detailed instructions concerning the possible combinations, product-specific risks, preparatory steps, indications and contraindications, etc. can be found in the Instructions For Use (IFU) accompanying the product, the description of the surgical technique, in the technical description of the product or on the appropriate catalogue sheet. ZimVie also recommends attending the appropriate user-training courses. The aforementioned documents and details of the training courses may be obtained from the appropriate representatives in the various countries. The manufacturer, the importer and the suppliers of ZimVie products are not liable for complications, injuries, the need for replacement procedures, implant failures, other negative effects or damages that might occur for reasons such as incorrect indications or surgical technique, unsuitable choice of material or handling thereof, unsuitable use or handling of the instruments, use of expired products, patient anatomy, overloading, asepsis and so on. The operating surgeon is responsible for any such complications or other consequences. It is also the operating surgeon's responsibility to properly instruct and inform the patient on the functions, handling and necessary care of the product and on all known product and procedure risks. As described in the Instructions For Use accompanying the product, poor bone quality, poor patient oral hygiene, heavy tobacco use, uncontrolled systemic diseases (diabetes, etc.), reduced immunity, alcoholism, drug addiction, and psychological instability may contribute to lack of integration and/or subsequent implant failure. Severe bruxism, clenching, and overloading, may cause bone loss, screw loosening, component fracture, and/or implant failure. Exposure to radiation and chemotherapy may impact durability and effectiveness of the implant. Dental implant patients should be instructed to consult with their physician prior to undergoing such treatment options.

Introduction

The BioBoost Effect

This Clinical Compendium summarizes current clinical evidence supporting the survival and success of the Trabecular Metal Dental Implant as reported primarily in peer-reviewed journal publications as well as recent, emerging results presented in conference abstracts, posters, and case documentation.

ZimVie initiated clinical studies of the Trabecular Metal Dental Implant in 2010 with a prospective, highly controlled immediate loading pilot study as well as a multi-national longitudinal data collection to monitor and gather data on implants in both healthy and clinically compromised patients in routine practice.^{1-3, 22, 23} Additional research has focused on immediate loading as the result of rapid recovery and documented bone ingrowth enhancing early secondary stability of the Trabecular Metal Dental Implant.¹⁻⁹ Compared to conventional titanium implants, gene expression analysis has resulted in staggering outcomes indicative of increased, new bone formation and vascularization as well as accelerated wound healing for Trabecular Metal Material. The accelerated healing pathways associated with Trabecular Metal Material are now known as the BioBoost Effect.^{10-17, 27, 28}

Following the successful performance of the Trabecular Metal Dental Implant in routine practice in which survival rates of patients with risk factors were similar to those of healthy patients,^{22, 23} ZimVie commenced the next phase of research to collect further evidence on the successful use of the Trabecular Metal Dental Implant in clinically compromised patients. Additionally, several clinicians embarked on their own research in this area, resulting in an array of data showing successful use and high survival rates of the Trabecular Metal Dental Implant in patients with a variety of systemic diseases and risk factors including diabetes, rheumatoid arthritis, and postablative oral cancer.²²⁻²⁴ While ZimVie is working closely with many clinicians around the globe to gather additional data and evidence on the successful application of Trabecular Metal Dental Implant in revision and rescue cases, we report herein an initial study and case documentation as an indication of successful use of this uniquely designed implant system in revision cases.³²

ZimVie's Trabecular Metal Material is a unique, highly porous biomaterial made from elemental tantalum with 80% porosity and structural, functional, and physiological properties similar to that of human trabecular bone, favorable conditions for the BioBoost Effect.³³⁻³⁷ ZimVie has experienced 20 years of clinical success of Trabecular Metal Implants in orthopedic applications. Evidence in this clinical compendium suggests that the Trabecular Metal Dental Implant is a promising treatment option for rapid recovery and risk management, with the possibility to treat patients with clinically challenging situations and provide an improved quality of life for underserved patients.

Hai Bo Wen, PhD.



Elnaz Ajami, PhD.



Rapid Recovery Studies: Two-Week Final Loading

Immediate Loading Of Trabecular Metal Implant Enhanced Titanium Dental Implants: Interim Results From An International Proof Of Principle Study.^{1, 2, 3}

Objective

- To evaluate 5-year clinical and radiographic outcomes of immediately-loaded Trabecular Metal Dental Implants in posterior jaws.

Methods

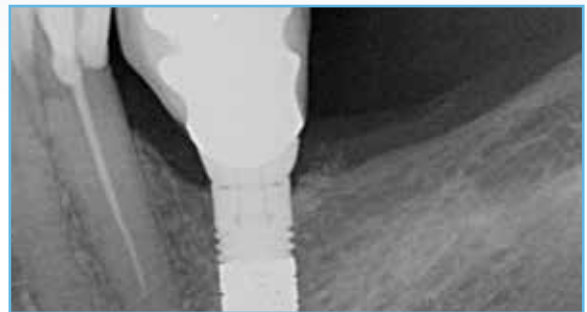
- Study centers in Germany and the Netherlands with enrollment commenced August 2010 and observed for 5 years.
- Patient exclusion criteria: smokers, need for bone augmentation, Type IV bone.
- Insertion torque of ≥ 35 Ncm required for immediate loading.
- Provisionalization without occlusion within 48 hours of implant placement; definitive restorations within 14 days.

Results

- 30 patients received 37 Trabecular Metal Implants.
- At 6 months, one implant failure was declared for a cumulative survival rate of 97.2%.
- No additional implant failures reported for patient annual follow-up observations up to 5 years.
- Marginal bone loss measurements: 0.46 ± 0.52 mm for 24 implants at the 3-year follow-up and 0.50 ± 0.49 mm for 18 implants at the 5-year study end.

Conclusions

- Within the limitations of this study, Trabecular Metal Dental Implants were clinically effective under immediate loading conditions in a controlled study.



Radiograph of study implant six months after implant placement.



Radiograph of study implant after two years in function.



Radiograph of study implant five years after implant placement.

Images courtesy of Dr. Marcus Schlee, Forstheim, Germany.

Rapid Recovery Studies: Two-Week Final Loading

Immediate Implant Loading: A Comparison Of Trabecular Metal And Tapered Screw-Vent Dental Implants.⁴

Objective

- To clinically and radiographically evaluate immediately loaded Trabecular Metal Implants and Tapered Screw-Vent Implants 18 months after insertion in partially edentulous patients.

Methods

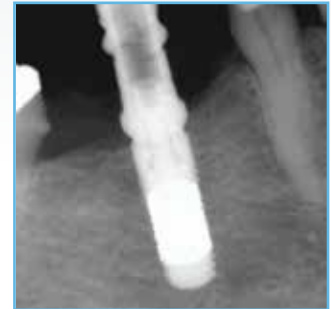- Patients were randomized into two groups: 26 patients (mean age 49 years) received 26 Trabecular Metal Implants (TM); 61 patients (mean age 54 years) received 61 Tapered Screw-Vent Implants (TSVM).
- Both implants studied have 0.5 mm machined collar with microgrooves.
- Temporary restorations were placed and adjusted out-of-occlusion within 48 hours. Final restorations were placed within 7 to 14 days on implants deemed to be clinically stable. Follow-up observations were performed at 1, 3, 6, 12, and 18 months.

Results

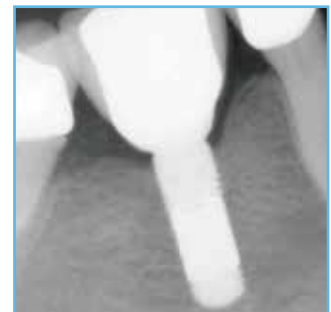- Distributions by location: 55% mandibular for TM Implant group; 61% mandibular TSVM Implant group.
- Distributions by length: 62% 10 mm, 35% 11.5 mm, and 3% 13 mm for TM group; 49% 10 mm, 41% 11.5 mm, and 10% 13 mm for TSVM group.
- Crestal Bone Loss (CBL) for TM Implants (0.5 mm machined collar) 0.44 ± 0.40 mm at one year; 0.46 ± 0.42 mm at 1.5 years ($p < 0.003$).
- Mean CBL for TSVM Implants (0.5 mm machined collar) 0.95 ± 0.62 mm at 1 year ($p < 0.003$); 0.97 ± 0.65 mm at 1.5 years ($p < 0.003$).
- No TM implant failures reported (100% survival); One TSVM Implant declared a failure prior to osseointegration (98.3% survival).

Conclusions

- Within 18 months of observations, all TM Implants survived. One TSVM Implant was lost prior to osseointegration.
- All surviving TM and TSVM Implants were deemed successful per the study success criteria. The TM Implants showed favorable clinical and radiographic results when placed with an immediate load protocol.



Radiograph of study implant at placement.



Radiograph of study implant after 18 months.

Images courtesy of Dr. Edoardo Brauner, Rome, Italy.

Immediate Loading Of Tantalum-Based Implants In Fresh Extraction Sockets: Long-Term Outcomes.⁵⁻⁷

Objective

- To determine the performance of Trabecular Metal Implants placed immediately into fresh extraction sockets, immediately provisionalized in occlusion, and definitively restored in two weeks.

Methods

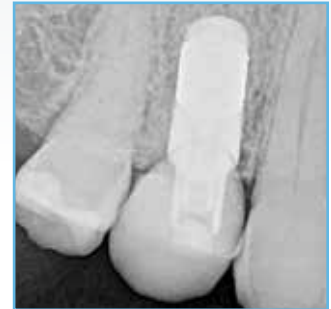- Records reviewed at a single private practice from 26 patients (68% female; mean age 43.3 ± 10 years) who received 26 single TM Implants in fresh extraction sockets.
- The gap between the implant and the buccal wall was packed with Puros Allograft in a 3:1 cortical to cancellous bone proportion.
- Provisional crowns were placed into immediate occlusion without lateral contacts and definitive lithium disilicate crowns were cemented (2) or screwed (24) at two weeks.

Results

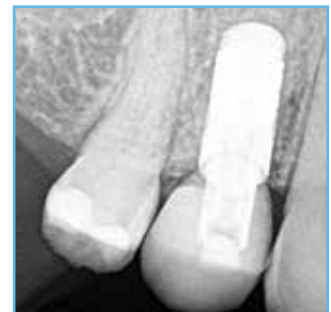- At placement, mean ISQ value = 71.6 ± 2.6 and final insertion torque > 40 Ncm for 24 implants.
- Distribution was primarily maxillary (61.5%), premolars and molars locations (80.8%), and Type III bone (88.5%).
- 100% success and survival rates reported at four-year follow-up.
- Mean crestal bone loss = 0.58 ± 0.34 mm at one year and 0.87 ± 0.36 mm at four years.
- Pink Aesthetic Scores were 13.4 at one year and 13.0 at the four-year follow-up.
- Mean peri-implant probing depth was 2.35 ± 2.4 mm at 1 year and 2.92 ± 2.6 mm at the four-year follow-up.

Conclusions

- Within the limitations of this retrospective study, immediate placement and occlusal loading of TM Implants resulted in predictable outcomes over the long term with stability of hard and soft tissues.



Radiograph of study implant after two years in function.



Radiograph of study implant after five years in function.

Images courtesy of Dr. Cristian Peron, Turin, Italy.

Rapid Recovery Studies: Immediate Placement

Immediate Placement Of A Porous-Tantalum, Trabecular Metal-Enhanced Titanium Dental Implant With Demineralized Bone Matrix Into A Socket With Deficient Buccal Bone: A Clinical Report.⁸

Objective

- To evaluate the combination of tantalum-based Trabecular Metal material and demineralized bone matrix (DBM) in deficient buccal alveolar bone regeneration associated with immediate implant therapy.

Case Presentation

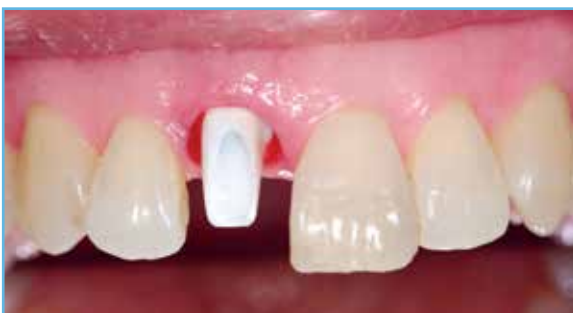- 65-year-old female presented with an infected central incisor having a large buccal plate defect postextraction.
- After osteotomy preparation, the palatal bone was tapped to create implant threads for implant positioning palatal to the buccal defect, leaving room for grafting material.
- The remaining socket was grafted with Puros DBM Putty.
- Implant insertion torque of 50 Ncm was achieved despite the facial plate defect.
- A custom healing abutment with removable partial restoration was placed immediately, and a CAD/CAM zirconia crown was placed at 3 months.

Results

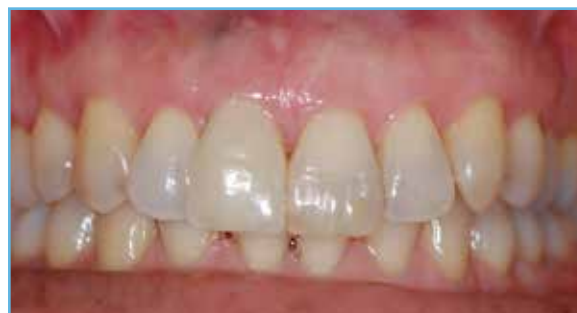- Peri-apical radiograph and CBCT scans at 6 months confirmed hard- and soft- tissue healing at the site.

Conclusions

- In the case evaluated, extraction and immediate implant placement were successfully performed even when buccal alveolar bone was missing.
- A combination of Puros DBM, a Trabecular Metal Implant, custom healing abutment, and an interim partial removable dental prosthesis may have provided an optimal environment for buccal alveolar bone regeneration and osseoincorporation, preserved the buccal blood supply, enhanced neovascularization, and controlled occlusal loading.



After immediate provisionalization and three months healing of the Trabecular Metal Implant, a patient-specific zirconia abutment and definitive crown were seated.



The Trabecular Metal Implant definitively restored at 3 months. CBCT scans conducted at 6 months confirm buccal bone regeneration.

Images courtesy of Dr. Sompop Bencharit, Chapel Hill, North Carolina.

The Influence Of Implant Design On Primary Implant Stability Simulating Immediate Placement Conditions Of The Anterior Maxilla.⁹

Objective

- Evaluation of primary stability of Trabecular Metal (TM) Dental Implants in simulated immediate placement conditions on a bovine rib.

Methods

- To simulate immediate implant placement conditions, the angle at which implant is placed in alveolar housing and available bone height to the nearest neighboring anatomical structure were obtained by reviewing 108 CBCT images of upper maxillary canines as well as lateral and central incisors. The average height and angle values were measured to be 10.1 mm and 20.7 degrees, respectively.
- The proximal part of the bovine rib was fixed in a thermostat-controlled water bath, and acrylic guides were secured to the specimen with fixation screws made to guide drills into the bone at approximately a 20 degree angle.
- A total of nine implants were placed, three of each design: TM Implants (3.7 x 11.5 mm), Tapered Screw-Vent (TSVM) Implants (3.7 x 11.5 mm), and competitive implants (3.5 x 11.5 mm).
- All implants were placed to a depth of 8.5 mm.
- The stability of implants was assessed by Resonance Frequency Analysis (RFA) using an Osstell Mentor device.

Results

- Similar ISQ values were obtained for all three implant systems; however, the mean ISQ was slightly higher for the TM Implants (61) compared with TSVM (60.4) and competitive implant.

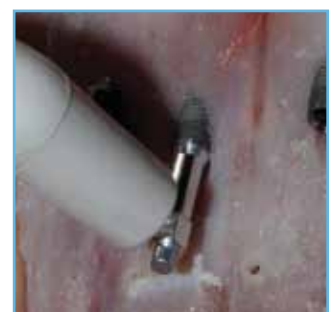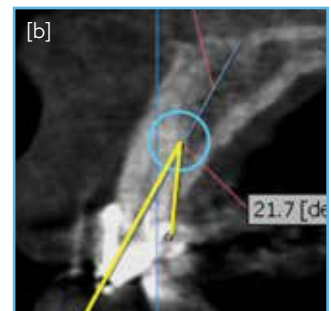
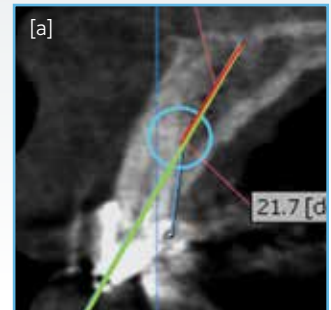
Conclusions

- In these simulated conditions, the TM Implant showed ISQ values comparable to TSVM and competitive implants, both well known for their high primary stability and well documented for immediate implantation and immediate loading. Therefore, the TM Implant achieved primary stability even in unfavorable conditions like angled implantation and incomplete submerging.

Preclinical results may not be indicative of clinical performance.

Third party trademarks and product names are the property of their respective owners.

Images courtesy of Dr. Marko Magic, Belgrade, Serbia.



CBCT images showing [a] ideal implant position and available bone height and [b] implant insertion angle [c] acrylic guide secured to a bone specimen to guide drills into the bone under a 20 degrees angle. [d] for implant stability measurements, Osstell Mentor device with suitable SmartPeg was attached to the implant, and RFA was conducted.

Rapid Recovery Studies: The BioBoost Effect

A Trabecular Metal Implant 4 Months After Placement: Clinical-Histologic Case Report.¹⁰

Objective

- To histologically evaluate a Trabecular Metal (TM) Implant retrieved 4 months after implant placement.

Case Presentation


- 54 year-old female was treated for moderate chronic periodontitis and one month later received placement of a TM Implant (4.7 mmD x 10 mmL) in a previously edentulous site.
- Patient presented four months later with inflammation of soft tissue, fistula, and an associated peri-implant bone defect requiring implant removal.
- Use of a piezoelectric device rendered a specimen with 1 mm of surrounding bone which was fixed, processed, and stained with methyl blue/acid fuchsin and also prepared for scanning electron microscopy.

Results

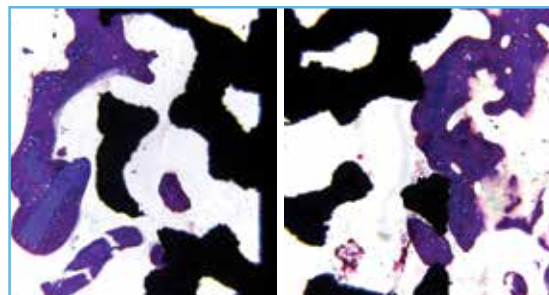
- Histology showed more bone in close contact with the TM Implant portion of the implant than to the titanium area of the implant.
- Bone in the TM Implant area of the implant resulted in a composite tissue with a woven and lamellar structure in a steady state without evidence of osteoclasts.
- In the TM Implant area, numerous irregularly displaced osteocyte lacunae, primarily globular in shape, were typical of cells found in woven bone; the surface of the trabeculae appear almost always smooth with very few indentations because of Howship lacunae.
- An osteoblast layer forming new bone was filling cavities in the basal bone adjacent to the inner titanium core of the implant.

Conclusions

- The finding of bone formation around the tantalum trabeculae suggests that TM Implant material can promote bone ingrowth for secondary implant stability. Additional research is required to determine if there are potentially advantageous properties of the TM Implant structure compared to titanium surfaces.



SEM micrograph at 4 months showing new bone in contact with, and grown between, Trabecular Metal pores.



Human histology at 4 months: Methyl blue/acid fuchsin stained histological sections showing healthy, woven bone filling the Trabecular Metal pores.

Images courtesy of Prof. Dr. Davide Zaffe, Modena, Italy.

Osseoincorporation Of Porous Tantalum Trabecular-Structured Metal: A Histologic And Histomorphometric Study In Humans."

Objective

- Histological and histomorphometrical evaluation of temporal bone ingrowth inside porous tantalum Trabecular Metal cylinders placed in human jaws.

Methods

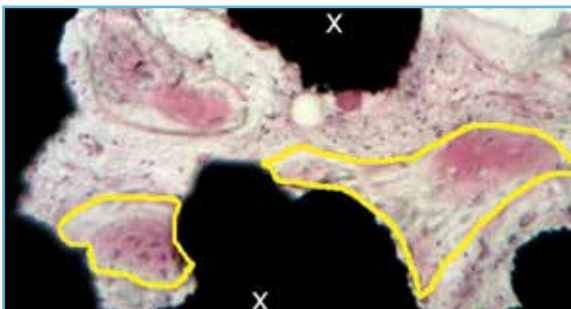
- 23 systemically healthy, partially edentulous subjects were scheduled for implant placement in one or both jaws and were required to have adequate residual bone to accommodate placement and explanation of a Trabecular Metal (TM) Implant cylinder (3.0 mmD x 5.0 mL).
- A total of 24 TM Implant cylinders were explanted at postoperative time points of 2, 3, 6, and 12 weeks.
- The explanted cylinders were fixed in formaldehyde, embedded in resin, and stained for histological analysis.
- The percentage of bone area density was assessed in three different regions to a depth of 0.5 mm, 1 mm, and 3 mm measured from the outside peripheral surface of the cylinder.

Results

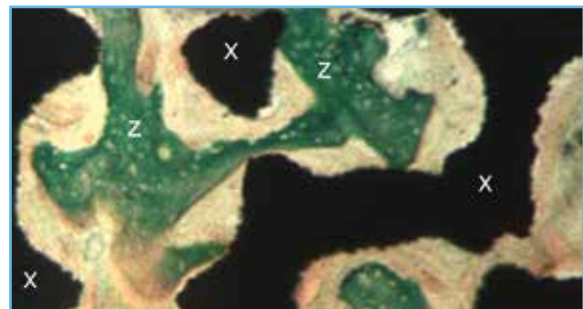
- Connective tissue infiltration with blood vessels inside the cylinders with minimal woven bone formation at the TM Implant walls was observed at 2 weeks.
- Osteoblasts in the connective tissue matrix located on the central pores deeper inside the TM Implant network was found at 3 weeks.
- Osteogenic tissue and larger amounts of bone around and inside the TM Implant pores along with extensive angiogenesis was evident at 6 weeks.
- Newly formed bone with osteoid edges lined by osteoblasts in contact with the internal and external surfaces of TM Implant cylinders along with blood vessels, marrow, and highly vascularized connective tissue inside the pores was observed at 12 weeks.
- Statistically significant higher percentages of calcified bone versus marrow was evident at 12 weeks compared to both 3 and 6 weeks.

Conclusions

- Osseoincorporation was achieved within a 3 mm depth of the Trabecular Metal cylinder over the course of 12 weeks via a rapid intramembranous-like bone healing pathway.



Newly formed bony trabeculae partially surrounded by a front of osteoblasts (inside yellow lines) in a peripheral pore at 3 weeks (Hematoxylin-eosin).



Bone trabeculae with osteoid tissue (z) along the edges inside the porous material (x) at 12 weeks, (Masson's trichrome).

Images courtesy of Prof. Dr. Celia Clemente de Arriba, Madrid, Spain.

Rapid Recovery Studies: The BioBoost Effect

Comparing Initial Wound Healing and Osteogenesis of Porous Tantalum Trabecular Metal and Titanium Alloy Materials.¹²

Objective

- To compare the expression patterns of genes involved in the initial bone healing of Trabecular Metal (TM) Implants and threaded titanium (Ti) cylinders.

Methods

- 2 TM Implants and 2 Threaded Ti cylinders with MTX[®] Surface (3x5 mm) were placed on each side of the mandibles of 12 healthy subjects. Cylinders were removed at two and four weeks post-surgery, and conventional TSV[®] Implants were placed in each site.
- Microarray analysis of genes involved in initial bone healing was compared between TM Implants and Ti groups.
- Clinical and radiographic evaluation was performed.



Threaded Ti and TM Implant Cylinders utilized in study.

Results

- Faster healing and increased adherence to the retrieved bone tissue in the TM Implant group was found as early as 2 weeks.
- 57% higher bone contact in TM Implant group compared to Ti was reported at 2 weeks.
- Significantly higher mean BIC values in the TM Implant group (40.06%) compared to Ti (21.52%) were measured.
- Bone remodeling occurred both in the center and peripheral areas of the TM Implant devices.
- Simultaneous upregulation of multiple genes related to osteogenesis, wound healing and blood vessel formation was found in TM Implant compared to the Ti group, starting at 2 weeks and appearing more pronounced at 4 weeks, as described below and shown in [Table 1].
 - Significant upregulation of genes specific to osteoblastic differentiation including bone morphogenic proteins (BMPs), runt-related transcription factor 2 (RUNX2), distal-less homeobox 5 (DLX-5), bone gamma-carboxyglutamate protein (BGLAP, aka Osteocalcin), and alkaline phosphatase (ALP) as well as collagens, indicative of early and more pronounced activation of osteoblastic differentiation, as well as faster formation and enhanced mineralization of extracellular matrix.
 - Significant upregulation of growth factors associated with wound healing and neovascularization including insulin growth factors (IGFs), epithelial growth factors (EGFs), and vascular endothelial growth factors (VEGFs), indicative of faster stimulation of neovascularization.
 - Significant upregulation of growth factors including Zinc finger protein GLI1 also known as glioma-associated oncogene (GLI1), EGFs, Fibroblast growth factors (FGFs), IGFs, Intercellular adhesion molecule (ICAM), and Transforming growth factor beta (TGFs) indicative of the enhancement of general wound healing.
 - Notably high expression of BMP3b, Col II, and Osteocalcin at 4 weeks, representing enhanced osteoblastic differentiation, matrix formation, and mineralization (shown in bold in Table 1).

Conclusions

- Within the limitations of this study, the use of TM Implants can facilitate early bone healing and attachment through enhancing gene expressions related to bone formation, wound healing, and blood vessel formation.

Table 1

In the table below, red text represents statistical differences of up-regulated markers. Blue represents statistical differences of down-regulated markers. Measurements at 2 and 4 weeks represent the fold regulation (magnitude difference) in gene expression in tissue analyzed surrounding the TM Implant material compared to titanium alloy. For example: At 2 weeks, BMP1 expression in tissue surrounding the TM Implant cylinder was significantly upregulated, with three times more BMP1 gene expression than found in tissue surrounding the threaded titanium cylinder.

**Gene Expression Differences Between TM Implant And Ti Cylinders
(Represented In Fold Regulation TM Implant/Ti)**

| | | Gene Expression TM Implants/Ti | |
|---|----------------------|--------------------------------|----------|
| | | 2 Weeks | 4 Weeks |
| Osteoblast Differentiation Related To Bone Formation | BMP1 | 3.2773 | -1.2169 |
| | BMP2 | 2.9811 | -2.9515 |
| | BMP3 | 3.5125 | 10.5422 |
| | BMP4 | 6.3606 | 2.2148 |
| | BMP5 | 5.275 | 10.4561 |
| | BMP6 | 1.6577 | -1.6081 |
| | BMP7 | 3.8526 | 6.7917 |
| | BMPRIA | 1.0962 | 5.9355 |
| | BMPRIB | 1.3939 | 1.6524 |
| | BMPR2 | 1.3006 | 2.8905 |
| | BMP-3b/BMP3B (GDF10) | 1.0275 | 133.2569 |
| | RUNX2 | -1.4249 | 10.7108 |
| | DLX5 | 3.5615 | 11.4817 |
| | BGLAP (Osteocalcin) | 2.9605 | 55.5571 |
| | ALPL | 2.1522 | 3.7804 |
| | Col I _1 | 1.4837 | 1.6005 |
| | Col I _2 | 1.865 | 5.2706 |
| | Col II _1 | 1.5009 | 44.4846 |
| Col III _1 | 1.2304 | 1.0328 | |
| Col V _1 | 1.9352 | 5.8948 | |
| Col X _1 | 1.9352 | -1.641 | |
| Col XIV _1 | 2.94 | 1.2618 | |
| Col XV _1 | -1.2177 | -2.0577 | |
| Growth Factors Associated With Wound Healing And Neovascularation | IGF1 | 1.0157 | 15.3149 |
| | IGF1R | 1.4004 | 10.6861 |
| | IGF2 | 1.1587 | 15.0029 |
| | VEGFA | -1.1735 | 3.1291 |
| | VEGFB | 1.4599 | 2.2684 |
| | VGFR1 (FL1) | -1.6984 | 6.2392 |
| | EGF | 1.8693 | 2.564 |
| | EGFR | 1.7808 | 4.4134 |
| Growth Factors Associated With General Wound Healing** | GLI1 | 2.312 | 12.7672 |
| | FGF1 | 1.029 | 5.255 |
| | FGF2 | -1.0287 | 4.7315 |
| | FGFR1 | 1.0911 | 7.5237 |
| | FGFR2 | 1.1089 | 10.2938 |
| | ICAM1 | -1.1982 | 2.638 |
| | TGFB1 | -1.37 | 2.2872 |
| | TGFB2 | -1.5449 | 7.0424 |
| | TGFB3 | -1.0528 | 4.5197 |
| | TGFBR1 | -1.1335 | 4.1544 |
| TGFBR2 | -1.0359 | 5.042 | |

**General wound healing is also evidenced by IGFs and EGFs above

Rapid Recovery Studies: The BioBoost Effect

New Bone Formation And Trabecular Bone Microarchitecture Of Highly Porous Tantalum Compared To Titanium Implant Threads: A Pilot Canine Study.¹³

Objective

- Evaluation of new bone formation activities and trabecular bone microarchitecture within the highly porous region of Trabecular Metal (TM) Implants and between the threads of Tapered Screw-Vent (TSV) Implants in fresh canine extraction sockets.

Methods

- Comparison of TM Implants (n=32, test) and TSV Implants (n=32, control) in dogs (n=8) in mandibular molar and pre-molar fresh extraction sites.
- Histomorphometric assay was conducted on the biopsies taken after healing at 2, 4, 8, and 12 weeks. Topographical and chemical analyses were also performed.

Results

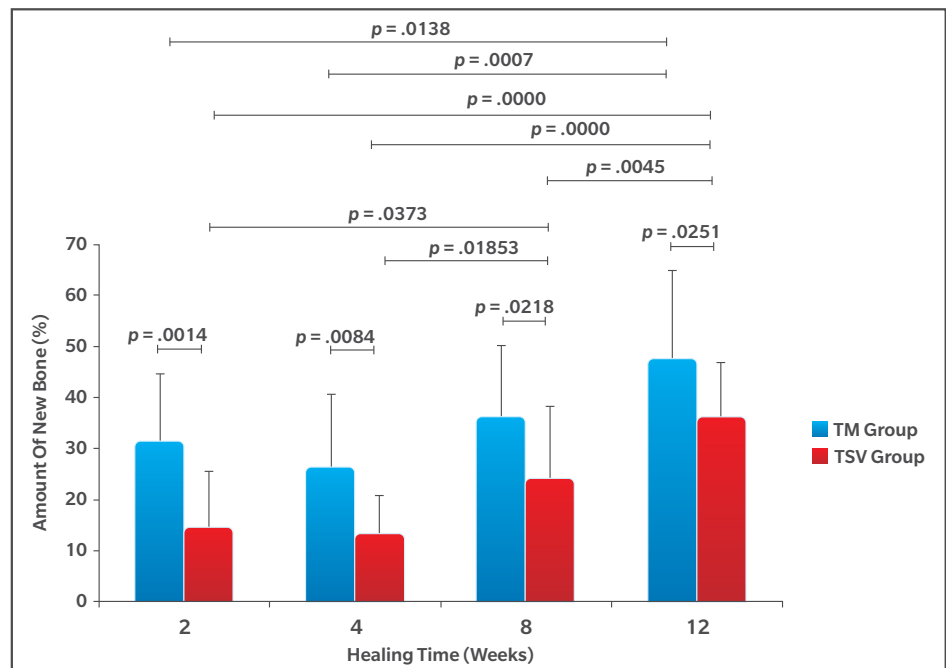
- Histomorphometry revealed significantly more new bone in the TM Implant than in the TSV Implants at all healing time points [Graph 1].
- Histologically, TM Implants exhibited more bone growth and dominant new immature woven bone at an earlier time point than TSV Implants [Graph 1].
- TM Implants exhibited an irregular faceted topography compared to a relatively uniform microtextured surface for TSV Implants.

Conclusions

- Within limitations of this study, the healing pathway associated with the highly porous midsection of the TM Implant may enable faster and stronger secondary implant stability than the conventional pathway.

Graph 1

Amount of new bone in the TM Implant compared to the TSV group at different healing time points



Preclinical results may not be indicative of clinical performance.

Porous Tantalum Increases Interfacial Bone Tissue Mineralization Compared To Titanium Threaded Section Of Implants.¹⁴

Objective

- Compare interfacial bone tissue quality between porous tantalum (Ta) layer (Trabecular Metal (TM) Implants) and threaded titanium (Ti) regions of the same implants during early healing.

Methods

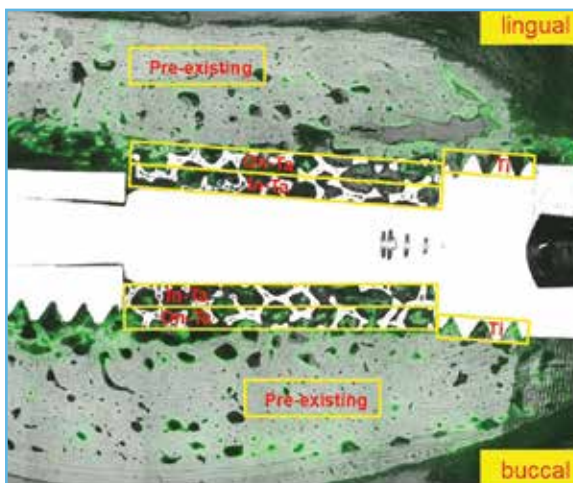
- 11 TM Implants retrieved from 5 dogs after 2, 4, 8, and 12 weeks of healing.
- Nanoindentations were used to measure plastic hardness (H) and elastic modulus (E) of bone.
- The mechanical properties of bone in four regions, i.e. pre-existing bone, on-Ta (< 0.35 mm deep region from the Ta surface of porous section), in-Ta (> 0.35 mm deep region from the Ta surface of porous section) and adjacent to the Ti screw thread, were analyzed.

Results

- At week 2, on-Ta layer had significantly higher E values than both in-Ta layer and at the screw thread regions.
- At week 4, differences in E and H values of interfacial bone were not significant between Ta layers and screw thread regions.
- At week 8, the Ta layers had significantly higher E and H values than the screw thread regions.
- At week 12, on-Ta layer had significantly higher E and H values than both in-Ta layer and at the screw thread regions.

Clinical Implications

- Within the limits of this research, the porous Ta section of the TM Implant increased bone tissue mineralization with stronger mechanical properties than the threaded titanium section of the implant.



Optical microscope image merged with florescent microscope image (calcein-labelled) to label new bone tissue. Nanoindentation sites outlined in yellow.

Images and data courtesy of Dr. Do-Gyoon Kim, Columbus, Ohio.

Preclinical results may not be indicative of clinical performance.

Rapid Recovery Studies: The BioBoost Effect

Biomechanical Analysis And Osteogenic Gene Expression On Porous Tantalum Implants Placed In A Gap Healing Model.^{15,16}

Objective

- Evaluation of removal torque values and osteogenic gene expression of implant-adherent cells to the Trabecular Metal (TM) Dental Implant surface on a rabbit gap healing model.

Methods

- 48 TM Implants and 48 modified Tapered Screw-Vent (TSV) (4.1 x 10 mm) Implants were placed bilaterally in the tibial metaphysis of 48 New Zealand white rabbits.
- The drilling was performed to a depth of 10 mm, with the exception of the final drill, having a diameter of 5.1 mm, which was used only in the medial site to a depth of 3 mm resulting in a circumferential 0.5 mm gap between the implant shoulder and the surrounding cortical bone. TM Implant (test) and TSV (control) Implants with identical apical design were anchored in the posterior cortex of tibia.
- Implants were subjected to removal torque (RT) test at 4, 8, and 12 weeks healing periods (24 in total) to evaluate the strength of osseointegration and immediately stored for mRNA expression analysis of key osteogenic markers. Histomorphometric analysis was also conducted (24 in total) and bone-implant contact (BIC) was measured.

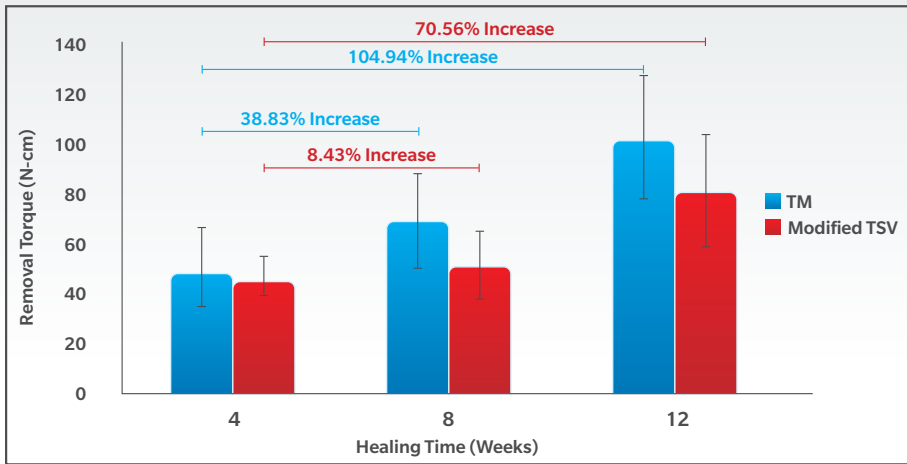
Results

- Significantly greater BIC over the entire implant surface for TM Implants compared to TSV Implants at all time points representing a difference of 142%, 90.1%, and 68.6% in favor of TM Implants at 4, 8, and 12 weeks, respectively.
- Significantly higher RT values at 8 weeks and 12 weeks for TM Implants compared to TSV with no differences at 4 weeks **[Graph 2]**.
- Significantly higher RT values at 8 weeks and 12 weeks compared to 4 weeks for the TM Implant group **[Graph 2]**.
- Similar RT values at 4 weeks and 8 weeks for the control group and higher values only at 12 weeks **[Graph 2]**.
- 9.8 fold upregulation of OSX, an essential transcription factor for osteoblast differentiation, on TM Implants at 4 weeks indicative of increased numbers of pre-osteoblast and osteoblast cells in early phase of the peri-implant healing process **[Graph 3]**.
- Greater than 2-fold upregulation of ALP, COL1A1, BSP, and OCN, expressed by committed pre-osteoblasts and osteoblasts by 12 weeks on TM Implants supporting the increased presence of osteogenic cells on the Trabecular Metal Implant surface **[Graph 4]**.
- The implication that a large number of osteogenic cells were present on the TM Implant surface as early as 4 weeks would lead to increased bone formation is supported by the significantly greater BIC at 4 weeks. Furthermore, greater BIC and RT for TM Implants at 8 and 12 weeks corresponds well with the upregulation of osteogenic markers at 12 weeks.

Clinical Implications

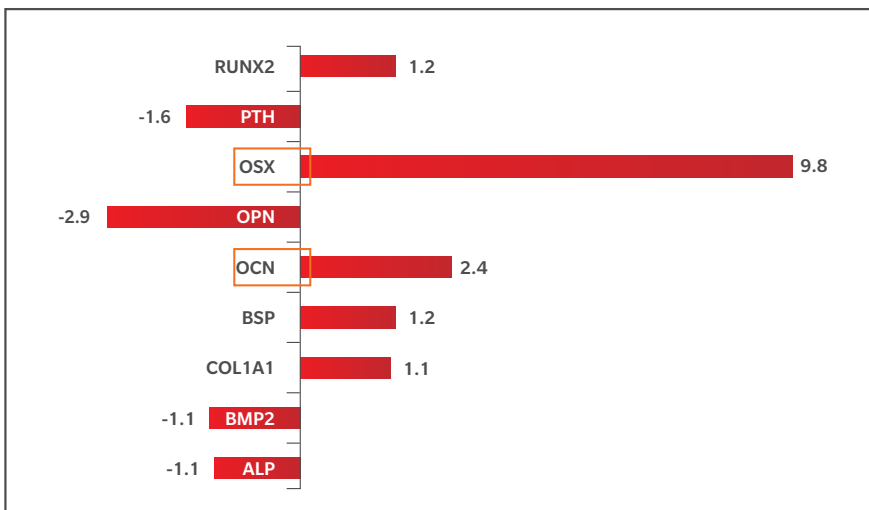
- Within the limits of this research, TM Implants may represent an alternative to conventional titanium implants to improve bone healing in surgical sites with an existing gap.

Preclinical results may not be indicative of clinical performance.

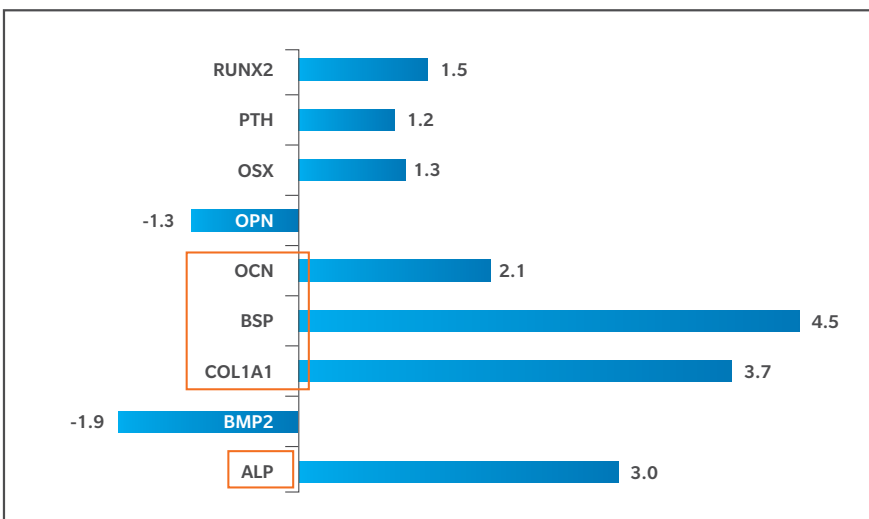


Graph 2
Removal torque values of TM Implant and TSV Implants at healing periods of 4, 8, and 12 weeks

Osteogenic gene expression after 4 and 12 weeks (Graph 3 and Graph 4, respectively) of healing on the TM Implant compared to a conventional titanium implant.



Graph 3
Up/Down Regulation
4 Weeks



Graph 4
Up/Down Regulation
12 Weeks

Risk Management Studies: Poor Quality Bone

Grafted Sites And Large Defects

Rehabilitation Of Extremely Atrophic Maxillae With Mineralized Allograft And Highly Porous Dental Implants.¹⁷

Objective

- The aim of this study was to evaluate the efficacy of placing Trabecular Metal (TM) Implants into fully augmented posterior maxillary jaws.

Methods

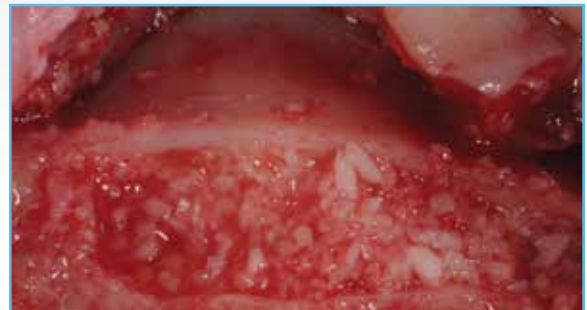- 22 TM Implants were placed in the posterior maxillae of 16 patients six months after maxillary sinus augmentation with Puros Allograft.
- Three months after TM Implant installation, the implants were uncovered and evaluated by a counter torque of 25 Ncm.
- Implant success was evaluated clinically and radiological 12 months after implant placement.

Results

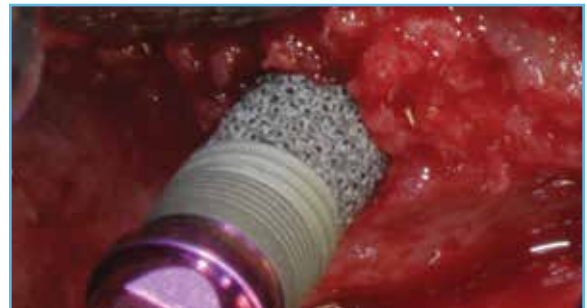- All implants tolerated 25 Ncm at second-stage surgery.
- Implant survival was 100% at 12 months.
- At the clinical level, there were no pathologies or detectable peri-implant marginal bone loss detected.

Conclusions

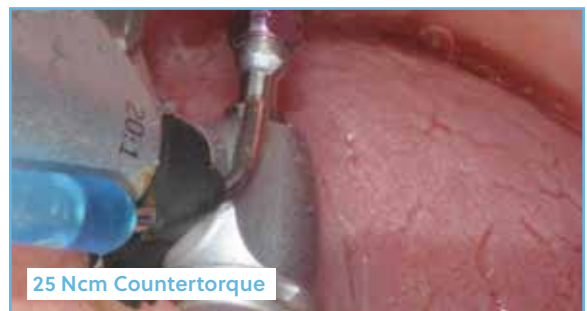- The favorable outcome in the rehabilitation of the atrophic posterior maxillary region documented in these cases was achieved by the placement of TM Implants in sites fully augmented with mineralized bone allograft without the necessity of harvesting autologous bone.



A crestal window was utilized to perform sinus grafting with Puros Allograft.



Six months after grafting, TM Implants were placed.



After 3 months of healing, all implants tolerated 25 Ncm of counter torque.

Images courtesy of Dr. Carlo Maria Soardi, Brescia, Italy.

Retrospective Analysis Of Porous Tantalum Trabecular Metal-Enhanced Titanium Dental Implants.¹⁸

Objective

- To compare marginal bone levels adjacent to Trabecular Metal (TM) and traditional titanium (Ti) Dental Implants placed with and without demineralized bone matrix (DBM) grafting material.

Methods

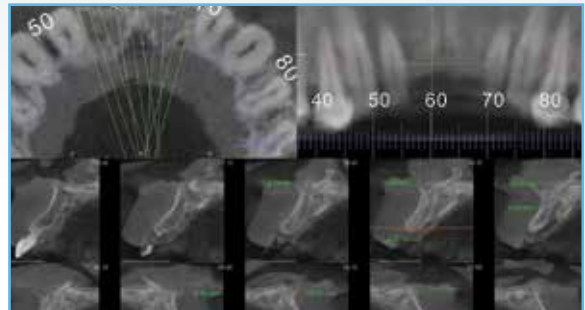
- Retrospective data on 82 patients with 205 implants (44 TM Implants and 161 Ti) was analyzed.
- Marginal bone level changes were compared after one year of implant loading of TM Implants and Ti Implants with and without DBM grafting.

Results

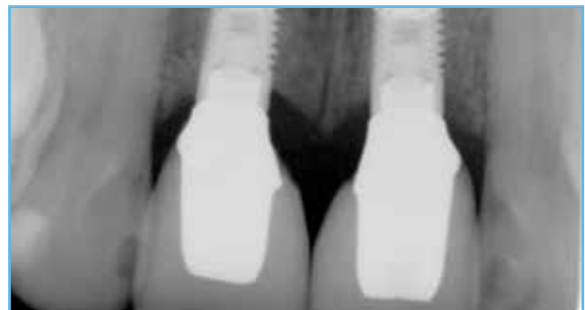- 100% implant survival was reported in the TM Implant group. In the Ti group, 98.1% survival was observed.
- Multivariate logistic regression analysis showed a 64% lower chance of bone loss in the TM Implant group than the Ti group (Odds Ratio: 0.36, 95% CI: 0.14-0.94).
- The TM Implant group had an average bone gain of 0.28 mm (SD=1.36). The Ti group had an average bone loss of 0.20 mm (SD=1.03).
- Implants with DBM had an average bone gain of 0.22 mm (SD=1.27), while implants without grafting had an average bone loss of 0.24 mm (SD=1.09).

Conclusions

- Within the limitations of this study, TM Implants with DBM maintained or gained marginal bone better than traditional implants.



Marginal bone level changes were compared after one year of implant loading of TM Implants and Ti Implants.



TM Implants maintained or gained marginal bone better than traditional implants.

Images courtesy of Dr. Sompop Bencharit, Chapel Hill, North Carolina.

Rapid Management Studies: Poor Quality Bone

Grafted Sites And Large Defects

Bone Modifications Around Trabecular Metal Implants Inserted Without Primary Stability. A Case Series With 3 Years Follow-Up.^{19, 20}

Objective

- To evaluate the outcomes of grafting and implant placement in a single surgical session in patients with extensive alveolar bone defects in posterior jaws.

Methods

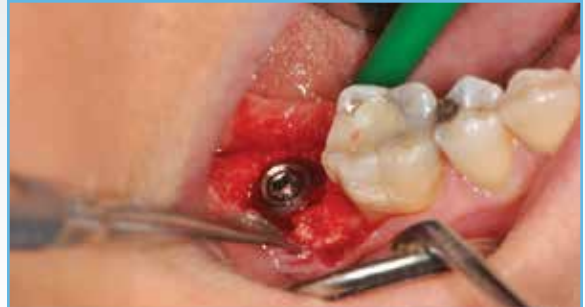- 10 consecutive patients treated within 3 months of extraction.
- After ridge exposure, implants were positioned in 4-wall defects without contact with pristine bone, and Puros Cancellous Allograft was packed around them to achieve stability.
- Sites were covered with resorbable membranes and soft tissues were sutured tension-free.
- Five months later, implants were restored in centric occlusion.

Results


- Survival rate was 100% for implants and grafts after 36 months.
- After 24 months follow-up, mean crestal bone level change = 0.15 ± 0.53 mm and mean bone gain at the defect site = 11.62 ± 1.04 mm. No significant bone level changes were reported at 36 months.
- Baseline ISQ values were undetectable. At uncovering at five months, ISQs increased to 71.33 ± 4.42 . After six months of loading, ISQ values were 79.33 ± 4.12 .

Conclusions

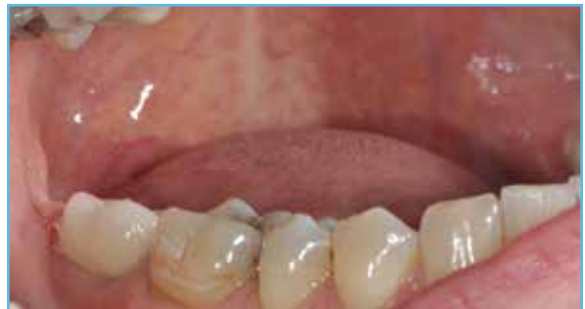- In this case series, osseointegration of Trabecular Metal Implants occurred independently of primary stability when stabilized with Puros Allograft and allowed to heal five months prior uncovering and restoration.



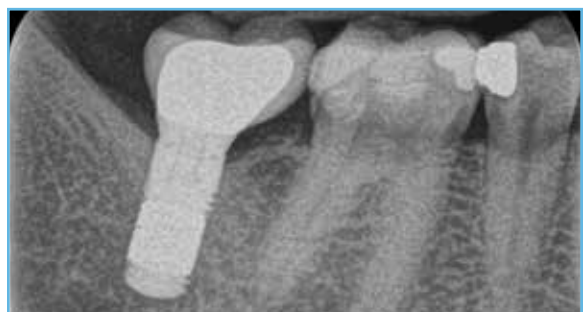Wide bone defect prevents a good primary stability at implant insertion.



Puros Cancellous Allograft was inserted to stabilize the implant and protected with a CopiOs® Pericardium Membrane.



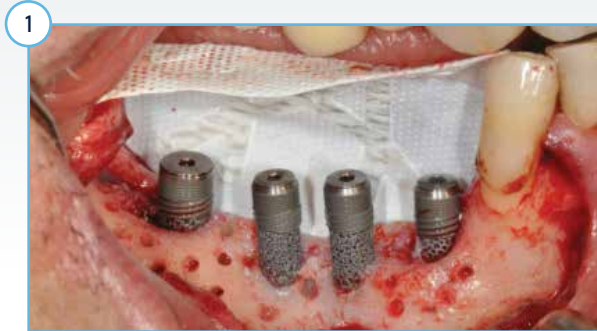The Trabecular Metal Implant received a provisional crown after five months of healing and the implant was definitively restored after six months. The clinical image above was taken at 3 year follow-up.



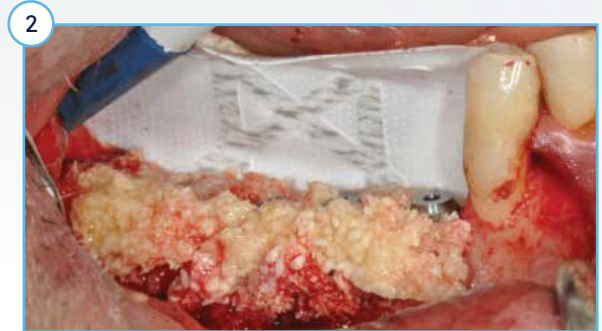At 3 year follow-up, the secondary stability ISQ parameters increased from 0 to 80 buccal-82mesial. The thickness of the crestal bone level appears to have increased.

Image courtesy of Dr. Stefano Bianconi, Bolzano, Italy.

A Novel Approach For The Coronal Advancement Of The Buccal Flap.²¹



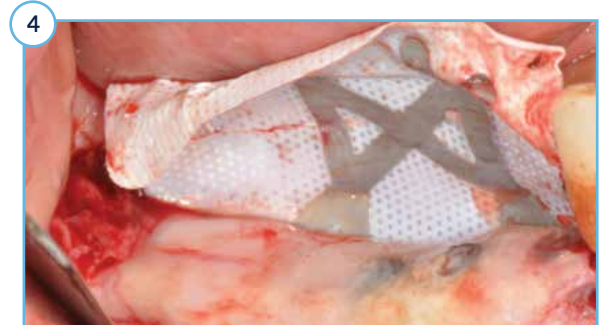Four Trabecular Metal Dental Implants with machined collars were placed using a standard surgical protocol for dense bone. Final insertion torque was between 45-59 Ncm for all the implants.



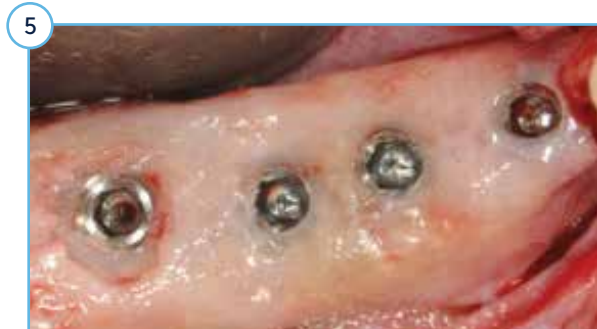Simultaneous bone grafts were placed using guided bone regeneration. A cortical-cancellous mix (50:50) (Puros Allograft Particulate) with PRGF was used as the graft along with a titanium reinforced non-resorbable d-PTFE membrane.



Radiographic view of the implants at 10 months postoperative. Note the restored ridge dimensions.

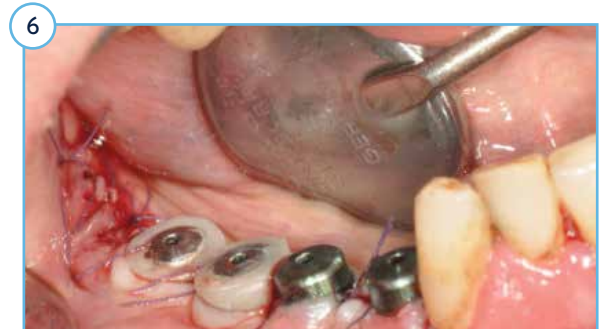

Note the clinical change in height and width of the alveolar ridge upon removal of the membrane.



The excess bone covering the implants was trimmed to expose the implants.

Images courtesy of Dr. Marco Ronda, Genova, Italy.



Healing collars placed on the implants upon re-entry at 12-months post-surgery. All 4 implants were stable at re-entry.

Risk Management Studies: Impaired Healing

Elevated Risk In Routine Clinical Practice

Prospective, Multicenter Evaluation Of Trabecular Metal-Enhanced Titanium Dental Implants Placed In Routine Dental Practices: 4-Year Report.^{22,23}

Objective

- Prospective, observational, multi-center clinical effectiveness study of Trabecular Metal (TM) Implants.

Methods

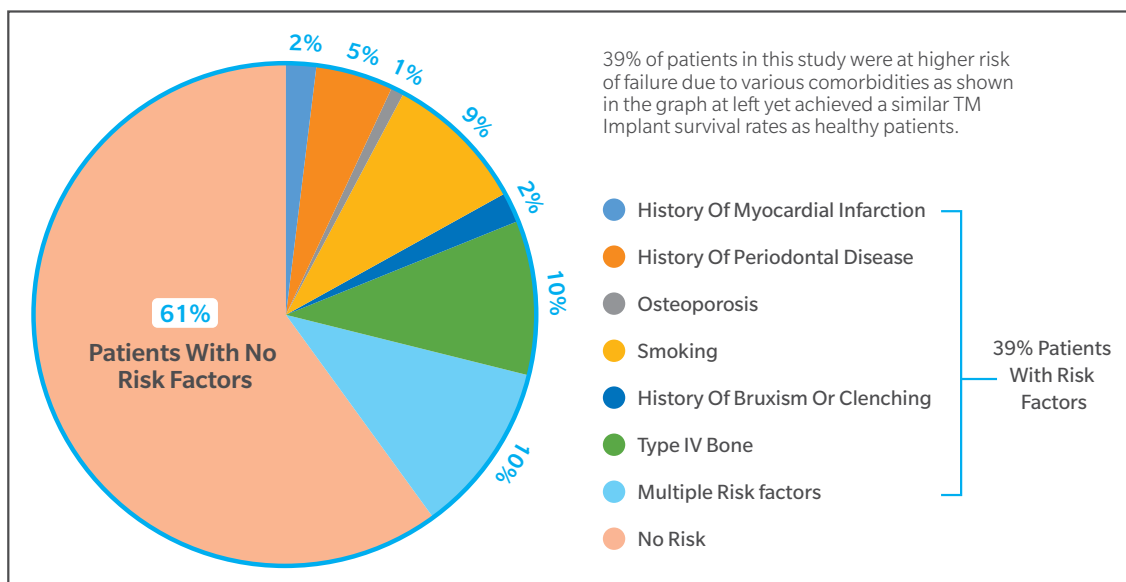
- 22 centers across Europe participated.
- Patient enrollment was not dependent on strict selection criteria, and patients with risk factors for bone loss or implant failure (smoking, history of periodontal disease, osteoporosis, type 4 bone, and bruxism) were treated with one or two implants in routine dental practices.
- TM Implant healing and restorative protocol determined by individual investigator.

Results

- 304 total patients enrolled and 428 TM Implants placed.
- 4-year follow-up includes 113 patients with 154 TM Implants.
- 44 (39%) patients with 41% of the TM Implants participating were considered at a higher risk for implant failure than healthy patients due to various comorbidities and physical characteristics **[Graph 5]**.
- TM Implant survival rate was 96.7% (n=88/91) in the healthy group and 96.8% (n=61/63) in the group with elevated risk.

Conclusions

- In this study, there was no significant difference in outcomes between patients with elevated risk factors and healthy patients.



Graph 5
Local And Systemic Factors (Patients)

Risk Management Studies: Impaired Healing

Postablative Cancer

Evaluation Of Highly Porous Dental Implants In Postablative Oral And Maxillofacial Cancer Patients: A Prospective Pilot Clinical Case Series Report.²⁴

Objective

- To evaluate the clinical efficacy of porous tantalum Trabecular Metal-enhanced titanium dental implants used for the prosthodontic rehabilitation of postablative cancer patients.

Methods

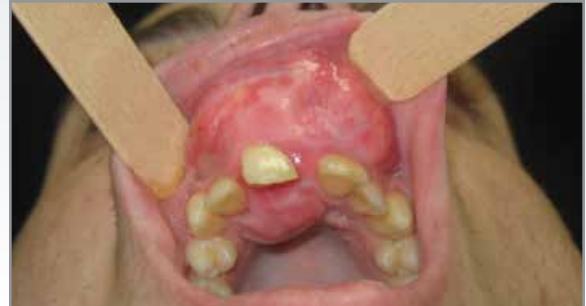- Six post-oncological patients (4 female/2 male; mean age 55 ± 25.5 years) were enrolled at an investigational university oral surgery center for a prospective pilot study.
- Each patient required surgical resection due to maxillofacial cancer; two received adjunctive radiotherapy. Following the required healing from resection surgery, (ranging six weeks to 1 year), implant placement surgeries for prosthetic reconstructions were planned.
- A total of 25 Trabecular Metal (TM) Implants (10 maxillary; 15 mandibular) were placed in the six patients with insertion torque > 35 Ncm. Implants per case ranged from 2 to 7.
- In all cases, implants healed submerged from 3 to 6 months and healing abutments were attached at second stage surgery to allow soft tissue healing (1 to 3 months). The timing of the definitive rehabilitation ranged from 3 to 8 months.

Results

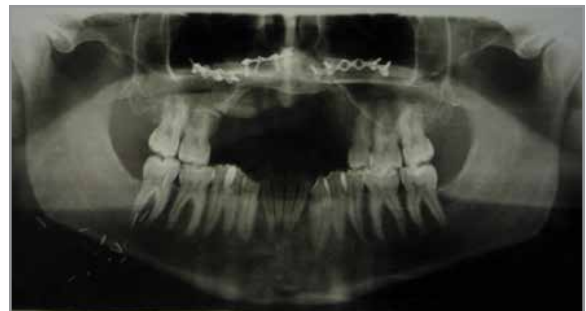- Implant survival was 100% after one year.
- Mean crestal bone loss after one year of function was $0.57 + 0.62$ mm.

Conclusions

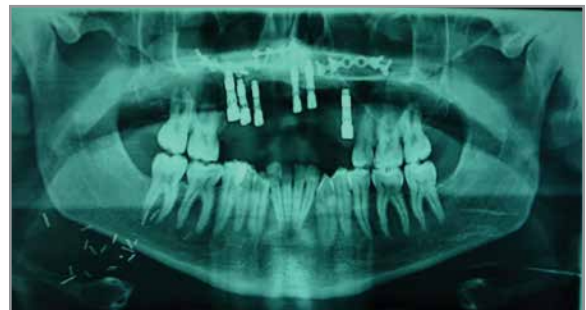- Post-oncological patients with large surgical mandibular and maxillofacial defects suffer from dysfunction, and within the limitations of this pilot study report were treated successfully with implant-supported rehabilitation using TM Implants.



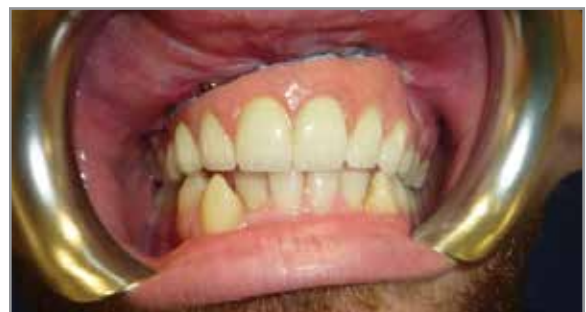Study patient #5 presented with chondroblastic osteosarcoma.



Maxillofacial treatment included tumor resection and fibula free flap reconstruction.



Six TM Implants were placed and allowed to heal for 6 months before second stage uncovering and placing healing collars.



Prosthetic rehabilitation was performed with a double structure of titanium-resin and porcelain. The definitive restoration was placed 3 months after second stage surgery.

Images courtesy of Dr. Edoardo Brauner, Rome, Italy.

Risk Management Studies: Impaired Healing

Systemic Disease: Patient Outcomes

Immediate Loading Of Tantalum-Based Implants In Patients With Systemic Diseases. Clinical And Radiographic Long-Term Outcomes.²⁵

Objective

- To retrospectively evaluate clinical and radiographic outcomes of immediate implant therapy with Trabecular Metal (TM) Implants in patients with systemic diseases 3 years after loading.

Methods

- A total of 15 patients (5 men, 10 women; mean age of 43.3 ± 10.4 years) with different systemic diseases like Sjogren Syndrome (SS), Morbus Crohn (MC), Heart Transplantation (T), Osteoporosis (O), Rheumatoid Arthritis (RA), and Diabetes (D) were treated with a total of 36 immediate TM Implants in conjunction with immediate loading [Table 2].
- Implants were placed in fresh extraction sockets and Puros Cortical and Cancellous Allograft in a 3:1 proportion was packed into the gap between the implant and buccal wall of the socket and extended up to the free gingival margin. No barrier membrane was used.
- The provisional acrylic restoration was immediately delivered after the surgical procedure.
- Two months later implants were definitively restored with lithium-disilicate crowns.

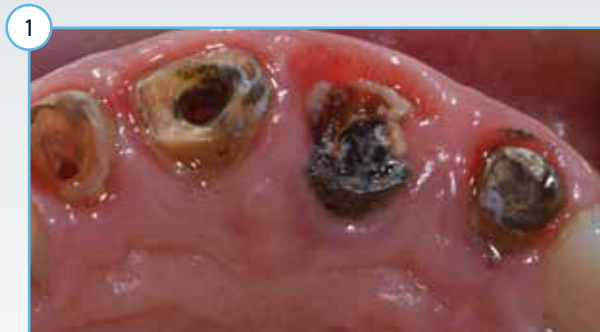Results

- All implants exhibited insertion torque values greater than 40 Ncm and RFA values 70.1 ± 2.6 at implant placement.
- At 3 years follow-up period, a survival rate of 97.2% was reported: 1 of the 36 implants failed after 4 weeks due to the lack of osseointegration (uncontrolled type II diabetes and heavy smoker).
- The marginal bone loss after 3 years follow-up was 0.583 ± 0.249 mm mesially and 0.63 ± 0.223 mm distally.
- No statistically significant changes in the full-mouth plaque score (FMPS) and full-mouth bleeding score (FMBS) were observed from baseline to 3 years.
- The mean pink aesthetic score was 13.1 at the 3-year follow-up.

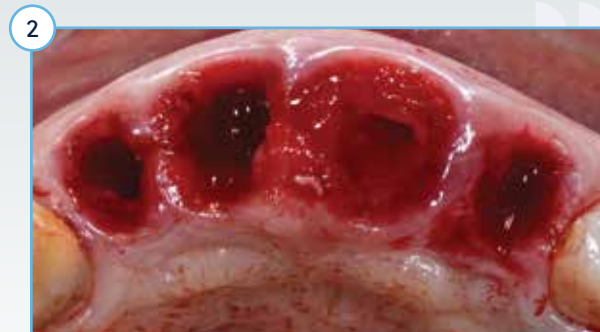Conclusions

- Within the limits of this study, the use TM Implants in postextraction sites with immediate provisionalization in patients with systemic diseases seems to be a safe and predictable procedure providing hard- and soft-tissue stability.

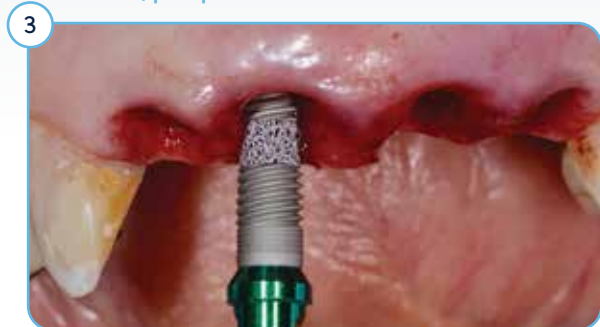The conclusion* is verbatim of referenced clinical study publication²⁵, with no inputs or alteration made by ZimVie. It has been retained as it is to maintain the sanctity of the study and its conclusion.



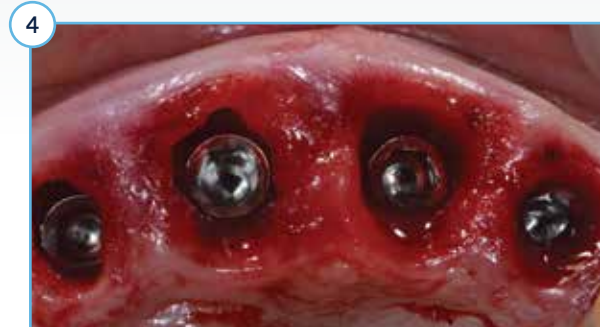1 Patient 6, preoperative view.



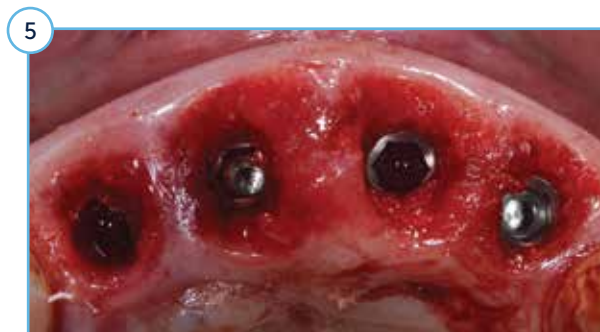2 Atraumatic extractions performed.



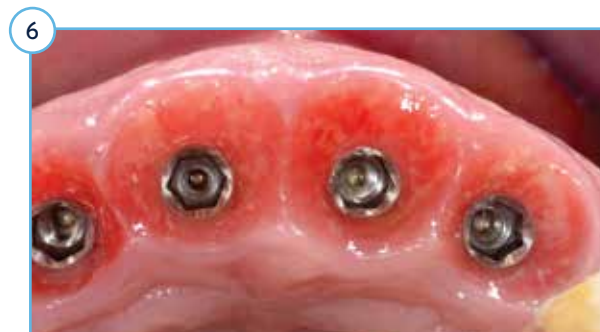3 TM Implant placement.



4 Four implants were placed immediately postextraction.



5 Puros Allograft filled the gap and extended up to the free gingival margin.



6 At four months post-implantation, soft tissue was healthy and stable.

Images and data courtesy of Dr. Cristian Peron, Italy.

Table 2

Patient Profile: Diseases, Age, Medications, Tobacco Use

| Patient | Disease | Sex/ Age | No. Of Implants | Location | Medications | Tobacco Use |
|---------|--|-------------|--------------------|----------|---|-------------|
| 1 | Morbus Crohn | M/35 | 1 | Maxilla | Infliximab, Prednisone | Y, >10/day |
| 2 | Sjogren Syndrome, Diabetes, Rheumatoid Arthritis | M/35 | 5 | Maxilla | Corticosteroids, Antihyperglycemic, Artificial saliva, Lubricants | N |
| 3 | Morbus Crohn | F/51 | 2 | Maxilla | Corticosteroids, Mesalamine | N |
| 4 | Rheumatoid Arthritis, Diabetes | F/66 | 2 | Maxilla | Corticosteroids, Antihyperglycemic | N |
| 5 | Morbus Crohn | F/34 | 1 | Maxilla | Corticosteroids | N |
| 6 | Diabetes | F/49 | 4 | Maxilla | Antihyperglycemic | Y, 10/day |
| 7 | Heart Transplantation | F/45 | 2 | Maxilla | Cyclosporine, steroids | N |
| 8 | Diabetes | M/51 | 1 | Maxilla | Antihyperglycemic, Antihypertensive | Y, >20/day |
| 9 | Osteoporosis | F/65 | 1 | Maxilla | N/A | N |
| 10 | Rheumatoid Arthritis, Diabetes | F/65 | 2 | Maxilla | Corticosteroids, Antihyperglycemic | Y, >10/day |
| 11 | Sjogren Syndrome | F/68 | 1 | Maxilla | Corticosteroids, Artificial saliva, Lubricants | N |
| 12 | Diabetes | M/59 | 2 | Mandible | Antihyperglycemic, Antihypertensive | Y, 5/day |
| 13 | Diabetes | M/71 | 2 | Maxilla | Antihyperglycemic | N |
| 14 | Diabetes | F/60 | 6 | Maxilla | Antihyperglycemic, Antihypertensive | N |
| 15 | Diabetes | M/69 | 5 | Maxilla | Antihyperglycemic | N |

Risk Management Studies: Impaired Healing

Immediate Loading Of Tantalum-Based Implants In Fresh Extraction Sockets In Patient With Sjogren Syndrome: A Case Report And Literature Review.²⁶

Objective

- To document a case report with a 30-month follow-up clinical and radiographic outcome of immediate loading using Trabecular Metal (TM) Implants in a patient with Sjogren Syndrome (SS).

Case Presentation

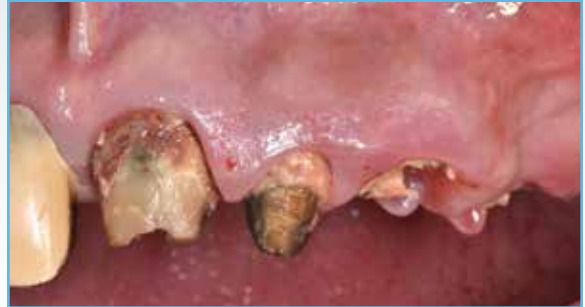- A 62-year-old woman patient with SS, rheumatoid arthritis, and type 2 diabetes mellitus presented with five severely carious teeth spanning from the maxillary central incisor to the second premolar. These teeth were atraumatically extracted and immediately rehabilitated with five TM Implants in fresh extraction sockets.
- Space between the implants and socket walls were filled with CopiOs Bone Grafting Particulate.
- An immediate prefabricated screw-retained provisional restoration was placed and adjusted in centric occlusion, providing a membrane-like stabilizing effect to the grafted area.
- After 2 months, a definitive metal/ceramic restoration was screwed into place and adjusted into full occlusion.

Results

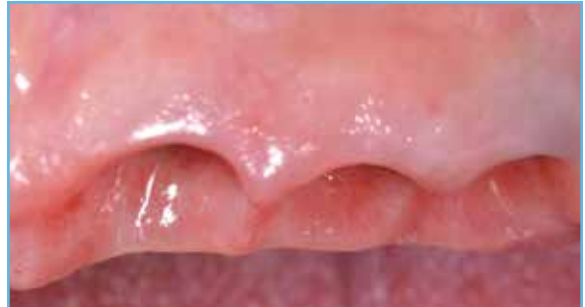- After three years, hard and soft tissues were stable and the case was reported to be successful.

Conclusions

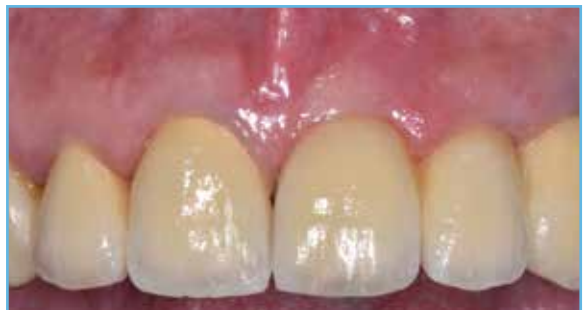- In this case, a patient with Sjogren Syndrome was successfully treated by using a minimally invasive, immediate technique to guide peri-implant healing and minimize discomfort and treatment time.



Five severely carious teeth were atraumatically extracted and immediately rehabilitated with five TM Implants in fresh extraction sockets. An immediate screw-retained prosthesis was utilized to stabilize the grafted area.



Excellent healing of soft tissues of patient with multiple systemic diseases.



After 3 years, continued restoration of aesthetics and function were reported.

Images courtesy of Dr. Cristian Peron, Turin, Italy.

Risk Management Studies: Impaired Healing

Systemic Disease: The BioBoost Effect

Transcriptomic Analysis Of Wound Healing Around Tantalum And Titanium In Diabetes.²⁷

Objective

- To examine the transcriptomic profiles of Trabecular Metal (TM) and Threaded Ti cylinders with MTX Surface in diabetic and healthy subjects during the initial phases of implant osseointegration.

Methods

- Two Threaded Ti and two TM Implant cylinders (3 x 5 mm) were placed on each side of the mandible of five healthy and six type 2 diabetic subjects.
- Devices were removed at 2 and 4 weeks post-surgery, and conventional Ti Implants were placed in each site.
- Microarray analysis of genes involved in the initial bone healing was compared between diabetic and healthy subjects and in response to TM Implant compared to titanium in diabetic patients.

Results

- Down-regulation of multiple genes indicating a slower healing response around both Ti and TM Implant in diabetic subjects as compared to healthy subjects at 2 weeks.
- Up regulation of 6 genes around TM Implant in diabetic subjects as compared to healthy subjects at 4 weeks, signaling enhanced bone formation and wound healing [Table 3].
- Significant upregulation of numerous other growth factors around TM Implant compared to titanium in diabetic patients in 4 weeks [Table 4], indicating earlier bone formation, wound healing, and vascularization.

Conclusions

- Up regulation of osteogenic gene expression around TM Implant at 4 weeks may facilitate early bone healing in diabetic patients.
- Within the limitations of this study, bone healing around TM Implant was faster than healing around titanium in diabetic patients.

Table 3

Upregulation Of Genes In Diabetic/Healthy Patients With TM Implant At 4 Weeks

| Gene Symbol | Fold Change At 4 Weeks |
|-------------|------------------------|
| IHH | 42.32 |
| CSF3 | 17.05 |
| EGF | 12.31 |
| CSF2 | 5.69 |
| BMPRI1B | 5.33 |
| CALCR | 4.32 |

Table 4

Upregulation Of Genes In TM Implant/Ti In Diabetic Patients At 4 Weeks

| Gene Symbol | Fold Change At 4 Weeks | Gene Symbol | Fold Change At 4 Weeks | Gene Symbol | Fold Change At 4 Weeks |
|-------------|------------------------|-------------|------------------------|-------------|------------------------|
| MMP10 | 39.95 | AHSG | 10.48 | ITGA1 | 7.08 |
| CALCR | 20.68 | SOX9 | 9.38 | PDGFA | 7.03 |
| FGF1 | 16.41 | SP7 | 8.59 | ITGA2 | 6.90 |
| NOG | 15.03 | EGF | 8.52 | TNF | 6.79 |
| BMP7 | 14.49 | BMPRI1A | 8.48 | ITGAS | 6.44 |
| FGFR2 | 13.24 | NFKB1 | 8.17 | FGFR1 | 6.22 |
| CSF3 | 13.12 | COL2A1 | 8.07 | TFGBR1 | 6.20 |
| CSF2 | 12.76 | COLSA1 | 7.69 | PHEX | 6.12 |
| BMPRI1B | 11.96 | TGFB1 | 7.33 | MMP2 | 6.11 |

Risk Management Studies: Impaired Healing

Systemic Disease: The BioBoost Effect

Transcriptomic Profiling Of Tantalum Metal Implant Osseointegration In Osteopenic Patients.²⁸

Objective

- To examine osteogenic gene expression around Trabecular Metal (TM) and Threaded Ti cylinders with MTX Surface in osteopenic subjects during the early phases of osseointegration.

Methods

- Two Threaded Ti and two TM Implant cylinders (3x5 mm) were placed on each side of the mandible of five osteopenic subjects.
- Cylinders were removed at 2 and 4 weeks post-surgery.
- Microarray analysis of genes involved in the initial bone healing was performed to compare TM Implant in relation to Ti Implants in osteopenic patients.

Results

- Significant upregulation of numerous growth factors around TM Implant compared to titanium in osteopenic patients at two and four weeks [Table 5], indicating earlier bone formation and mineralization.
- Upregulation of genes related to osteoblast differentiation including Alkaline phosphatase gene (ALPL) (10 fold increase) and BGLAP (Osteocalcin) in TM Implant in relation to Ti in osteopenic patients at 4 weeks.
- Increased expression of growth factors stimulating osteoblast differentiation including BMP4 and TGFB3 at 2 weeks, and TGFB2 at 4 weeks in TM Implant group.
- Upregulation of FLT1 at 4 weeks and significant fold increase in cadherin-11 (CDH11) at 2 weeks in TM Implant group. Both genes have a role in controlling bone formation rate and bone mass.
- Upregulation of angiogenesis associated genes in TM Implant group at 2 weeks including FGF2, ITGA1, ITGB1 (significant increase), and at 4 weeks including VEGFB, EGF, ITGA1.
- Increased upregulation of different integrin receptor ITGA1 and ITGA2 and ITGFB1 in TM Implant group when used in osteopenic patients, suggesting better healing and tissue adhesion.
- Upregulation of collagen genes in TM Implant group at 2 weeks including COL15A1, COL1A, COL1A2, COL3A1 (significant fold increase), and at 4 weeks including COL2A1. Both COL1A1 and COL3A1 are localized in bone tissue and upregulated in the early stages of osteoblast differentiation.

Conclusions

- Within the limitations of this study, the use of TM Implants may improve osseointegration in osteopenic patients by activating the osteogenic signaling pathways during early bone formation and mineralization.

Table 5

Red represents statistical differences of up-regulated markers. Blue represents statistical differences of down-regulated markers. Measurements at 2 and 4 weeks represent the fold regulation (magnitude difference) in gene expression in tissue analyzed surrounding the TM Implant material compared to threaded titanium cylinders in osteopenic patients

| Gene Expression Differences: TM Implant/Ti | | |
|--|----------|----------|
| Gene | 2 Weeks | 4 Weeks |
| ALPL | 1.2958 | ↑ 10.267 |
| BGLAP | 1.1872 | ↑ 3.8334 |
| BMP4 | ↑ 2.3184 | 1.176 |
| TGFB2 | 1.5557 | ↑ 6.0062 |
| TGFB3 | ↑ 2.2786 | 1.0549 |
| CDH11 | ↑ 2.023 | 1.3055 |
| FLT1 | 1.6261 | ↑ 2.0665 |
| EGF | ↑ 0.1831 | ↑ 2.991 |
| FGF2 | 2.3888 | 1.0899 |
| VEGFB | -1.4688 | ↑ 3.5104 |
| ITGA1 | ↑ 2.7695 | ↑ 3.2849 |
| ITGB1 | ↑ 2.6248 | 1.398 |
| COL15A1 | ↑ 3.2336 | 0.6764 |
| COL1A1 | ↑ 2.1891 | 1.042 |
| COL1A2 | ↑ 4.9625 | 1.928 |
| COL2A1 | 0.6156 | ↑ 2.3359 |
| COL3A1 | ↑ 5.7326 | 0.6582 |

Risk Management Studies: Impaired Healing

Prior Infection

Immediate Loading Of Trabecular Tantalum-Based Implants Placed In Infected Sites With Full Ceramic Restorations. 1-Year Clinical Evaluation.²⁹

Objective

- To describe the procedure for immediate Trabecular Metal (TM) Implant placement in fresh extraction sockets with periapical lesions and immediate loading using provisional restorations immediately after surgery.

Methods

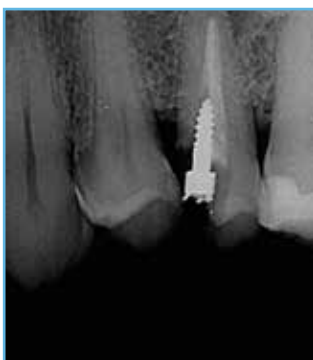- A total of 10 patients with chronic periapical lesions underwent extraction and careful debridement using microscopy, after which 10 TM Implants were placed immediately with a minimum insertion torque >35 Ncm.
- Puros Cancellous and Cortical Allograft was used in the gap between implants and the buccal bone.
- The implants were loaded immediately with provisional restorations to protect and maintain the blood clot and bone graft during the implant and graft healing phase.
- After two weeks, screw-retained final restorations were delivered and torqued to 30 Ncm.

Results

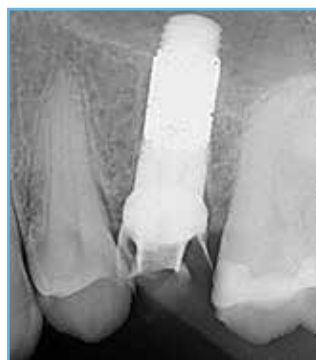- At 1 year, the success rate of implants and prostheses placed was 100%.
- The pink aesthetic score averaged 13.4.
- The peri-implant bone loss after 1 year averaged 0.207 ± 0.245 mm mesial and 0.201 ± 0.213 mm distal.
- All patients reported full satisfaction for mastication function, phonetics, and aesthetics.

Conclusions

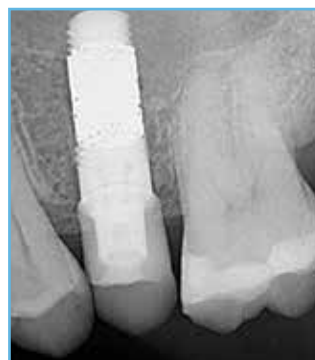- Within the limitation of this case series, the use of TM Implants with an immediate placement and loading may be considered as a safe, effective and predictable treatment option for the rehabilitation of fresh postextraction infected sockets when following a suitable protocol.



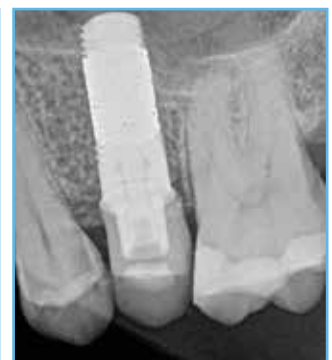Preoperative view.



Immediate TM Implant placement.



One year postoperative X-ray radiograph.



X-ray radiograph after four years shows continued survival and stable bone levels.

Images courtesy of Dr. Cristian Peron, Turin, Italy.

The conclusion* is verbatim of referenced clinical study publication²⁹, with no inputs or alteration made by ZimVie. It has been retained as it is to maintain the sanctity of the study and its conclusion.

Risk Management Studies: Impaired Healing

Prior Infection

A Retrospective Survival Study Of Trabecular Tantalum Implants Immediately Placed In Posterior Extraction Sockets Using A Flapless Technique.³⁰

Objective

- To retrospectively review the performance of Trabecular Metal (TM) Implants placed immediately with a flapless technique into posterior extraction sites of patients at a private practice.

Methods

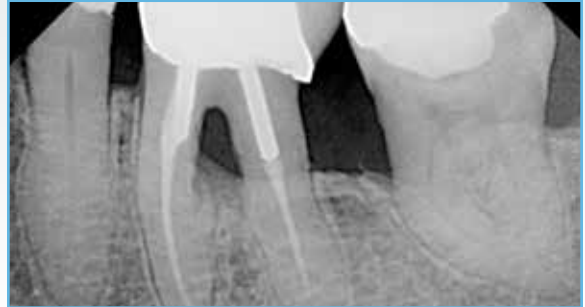- Forty-two patients (52% male, mean age 60.2 ± 7.6 years) required extractions of 44 premolars or molars (77% maxillary). Thirty-three patients (78%) had periodontal disease. Five patients were diabetics, and six patients were smokers.
- Crestal sinus grafts were augmented with Puros Cortical Allograft. Other defects were filled with Puros Cancellous Allograft in thick tissue biotypes or a Puros Cortical-Cancellous Allograft Mix [70:30] in thin tissue biotypes.
- TM Implants achieving final insertion torque ≥ 40 Ncm in the maxillary posterior were provisionalized immediately.

Results

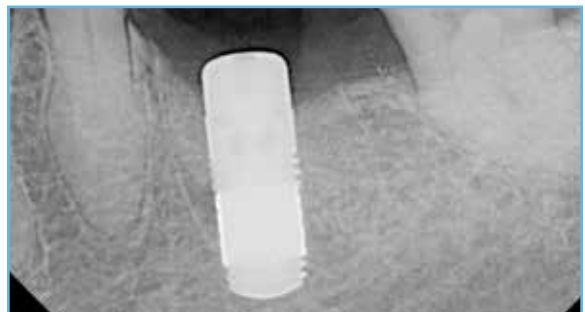- Eight implants met criteria for immediate provisionalization.
- 35 implants (88.1%) healed in a two-stage protocol and definitive crowns were installed after 8 months (average) from placement.
- Mean duration of follow-up was 25.0 ± 12.1 months.
- One implant failure was observed prior to prosthetic loading.
- Cumulative survival rate of 97.7%.

Conclusions

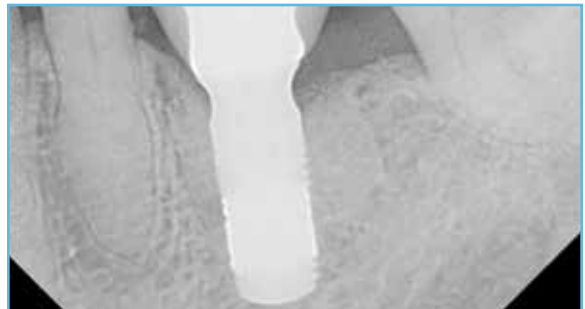
- Within the limitations of this study, pre-existing periodontitis and other risk factors did not influence implant survival or success.
- Also within the study limits, TM Implants immediately placed into posterior extraction sites show high survival following loading.



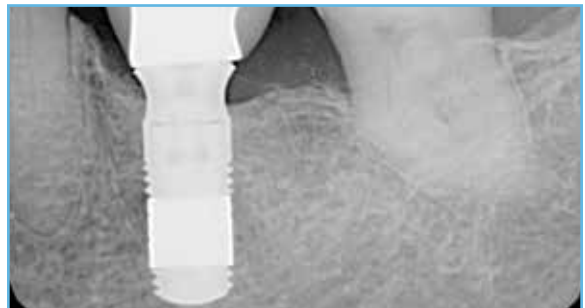Periodontitis and bone loss resulted in molar extraction.



A TM Implant was placed immediately into the extraction site.



Radiograph after two months in function.



Radiograph after five years show stable bone levels.

Images courtesy of Dr. Edgard El Chaar, New York City, New York.

Evaluation Of Different Implant Designs In A Ligature-Induced Peri-Implantitis Model: A Canine Study.³¹

Objective

- Clinical and histological evaluation of the influence of ligature-induced peri-implantitis on Trabecular Metal (TM) compared to Tapered Screw-Vent (TSV) Dental Implants in a canine extraction socket model.

Methods

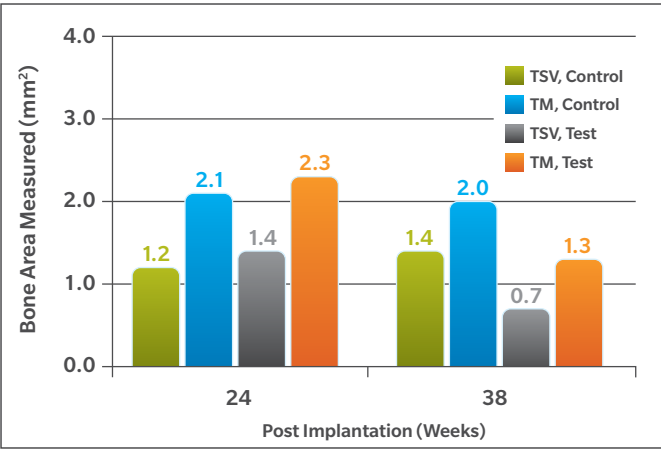
- Thirty-two TSV and 32 TM Implants (4.1 × 13 mm) were placed bilaterally in eight dogs immediately after extraction of the mandibular premolars (P3, P4) and molars (M1, M2).
- Peri-implantitis was induced after 12 weeks of normal healing in four dogs (the test group) via the placement of ligatures subgingivally around the implant necks.
- Routine oral hygiene prophylaxis consisting of brushing and rinsing with 0.12% chlorhexidine gluconate solution was performed in the control group only.
- Peri-implantitis indices, such as plaque evaluation, incidence of bleeding, and probing pocket depths were clinically evaluated during the observation period.
- Histologic sections were obtained for histologic and histomorphometric assessments after 24 or 28 weeks.

Results

- Clinical and histological osseointegration of all implants was in both groups.
- Significant peri-implant bone loss and significantly greater pocket probing depths were measured in the test group from the induced peri-implantitis, without pocket depth extending to the porous section of the TM Implants.
- No difference in mean bone-to-implant-contact values for control vs test groups or for different implant designs was reported.
- Significantly increased bone formation exhibited between the inner and outer diameter of the TM Implants than the TSV Implants in both the test and control groups [Graph 6].

Clinical Implications

- In this study, the incidence of peri-implantitis observed is independent of implant design. Bacterial infection was not observed inside the TM pores.



Graph 6
Bone Area Measurements in Induced Peri-Implantitis Model

Preclinical results may not be indicative of clinical performance.
Images and data courtesy of Dr. Do-Gyoon Kim, Columbus, Ohio.

Revision Therapy Studies and Cases

Replacement Of Failed Implants

Immediate Placement of Trabecular Implants in Sites of Failed Implants³²

Objective

- To evaluate dental implant survival after five years in cases in which failed implants were immediately replaced by Trabecular Metal (TM) Implants.

Methods

- 16 failed implants in 14 patients were atraumatically explanted.
- Fibrous tissue was curetted from the walls of the osteotomy, and the sites were treated with pellets of 0.12% chlorhexidine for two minutes.
- TM Implants were immediately placed, and primary stability was achieved by increasing the diameter or length of the implant compared to the failed implant.
- Implants with gaps were grafted with Puros Cortico-cancellous Allograft or Healos xenograft.
- Implants not requiring a membrane received a healing collar for one-stage placement.
- Implants were definitively restored 8 to 10 weeks postoperatively with stock contour abutments and cemented crowns.

Results

- 15 of 16 implants (93.8%) had successful outcomes and remained in function after 5 years.
- Radiographs revealed excellent bone-to-implant contact with less than 1 mm of crestal bone loss.

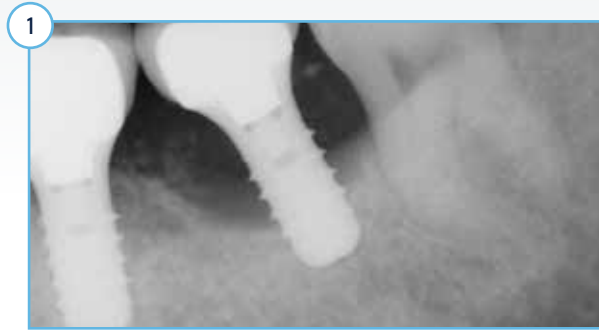Conclusions

- Within the limitations of this study, immediate placement of a TM Implant appears to be both a suitable and reliable option for patients with a failing or failed implant, with survivability and bone-to-implant contact that meets or exceeds the current expectation of successful implant placement and long-term function.

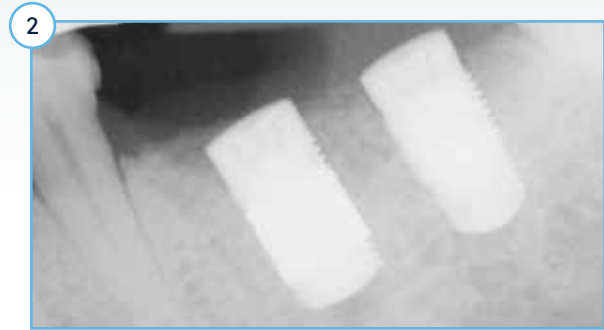
Revision Therapy Studies and Cases

Replacement Of Failed Implants

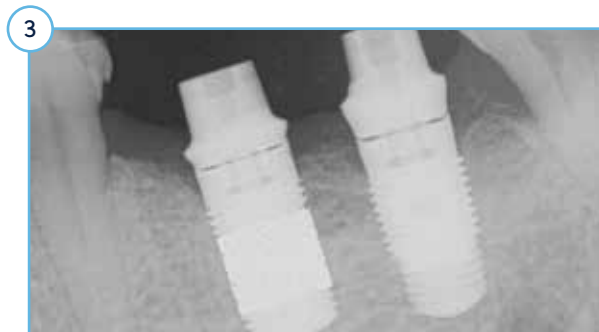Revision Of Peri-Implantitis-Related Failure With Trabecular Metal Implant: 6-Year Follow-Up.



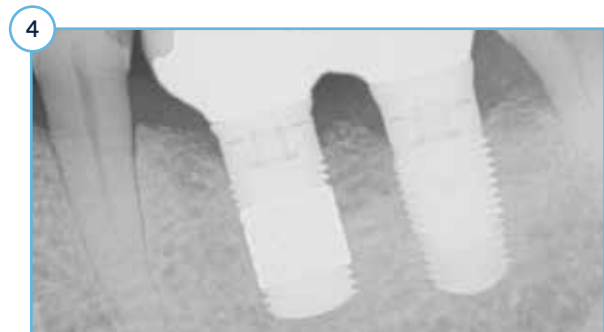Uncontrolled diabetic patient presented with significant peri-implantitis and bone loss. Implant was removed after two years in function. Site was grafted with Puros Cortico-Cancellous Allograft and CopiOs Pericardium Membrane.



After four months, a Tapered Screw-Vent (TSV) Implant was placed in the grafted site. Additionally, the adjacent implant was deemed a failure due to loss of integration and was explanted. A TM Implant was placed immediately in the extraction site with no grafting, with excellent primary stability and insertion torque > 20 Ncm.



Three months after implantation, Hex-Lock® Short Abutments were placed. Radiograph taken prior to completion of abutment seating. The final restoration was seated two weeks later.



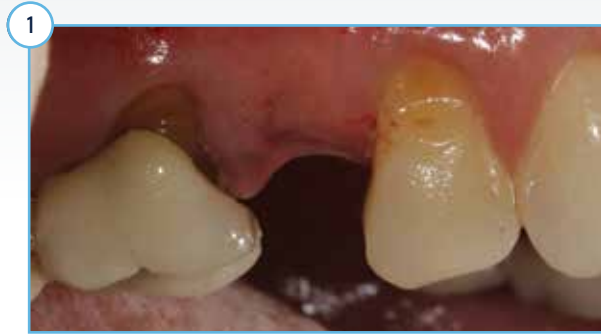TM and TSV Implants after six years in function. Bone level around the TM Implant remains stable. Minor bone loss is observed around the TSV Implant.

Images courtesy of Dr. Michele Dimaira, Flourtown, Pennsylvania.

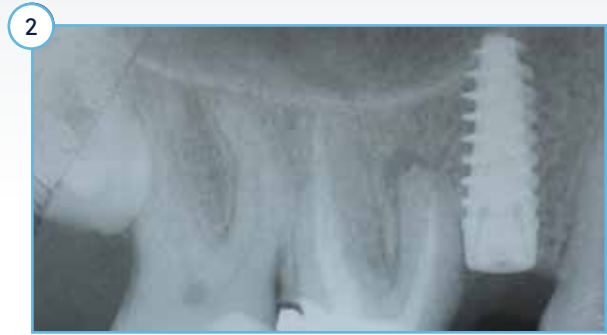Revision Therapy Studies and Cases

Replacement Of Failed Implants

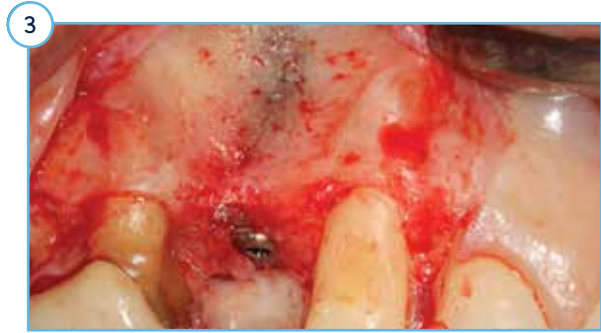Revision Of Failed Implant With Guided Bone Regeneration And Trabecular Metal Implant: 3-Year Follow-Up.



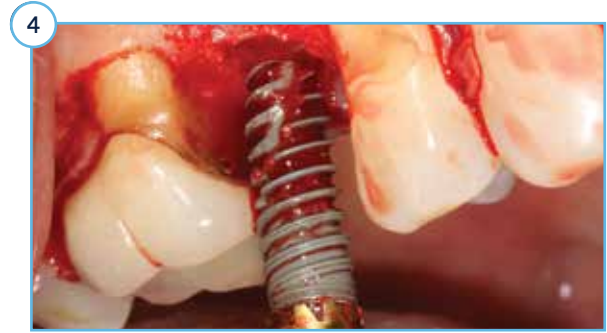
1 Patient presented with sinus infection, pain, and recession adjacent to failing implant.



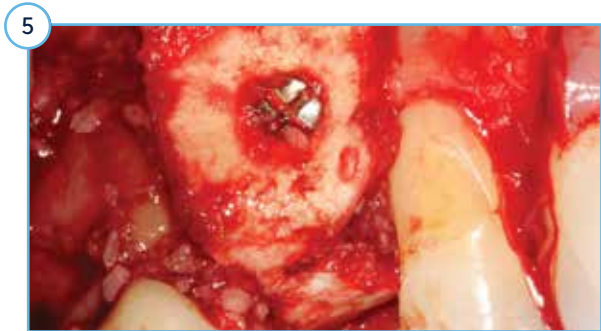
2 Preoperative PA and a CT scan revealed loss of buccal plate.



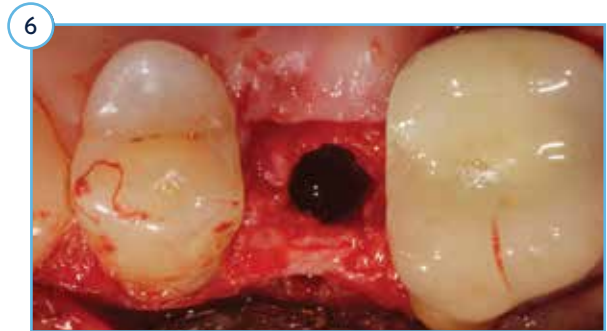3 Exposure revealed buccal fenestration and dehiscence calling for implant removal.



4 Failed implant was explanted with implant removal tool.

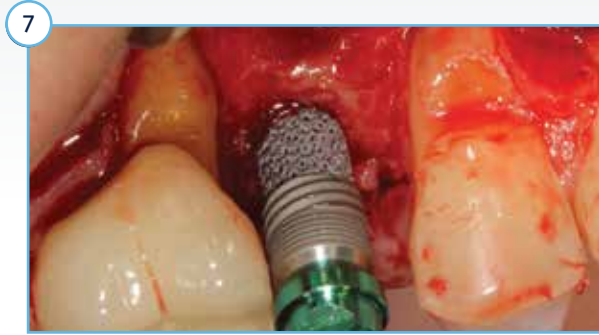

5 Puros Cortical-Cancellous Mix Allograft was utilized to augment the buccal defect. A curved, pre-shaped collagen membrane was secured with a fixing screw to cover the graft.

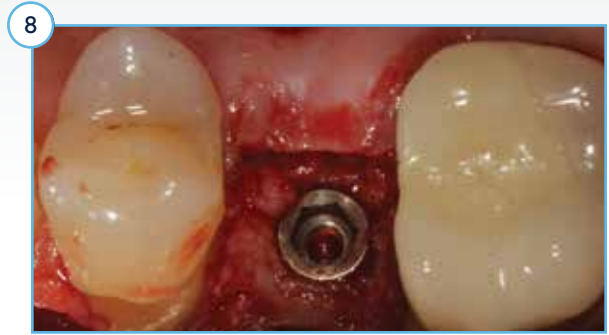

6 After four months of guided bone regeneration, the CT scan revealed successful regeneration buccal augmentation. The membrane fixation screw was removed and the osteotomy was prepared.

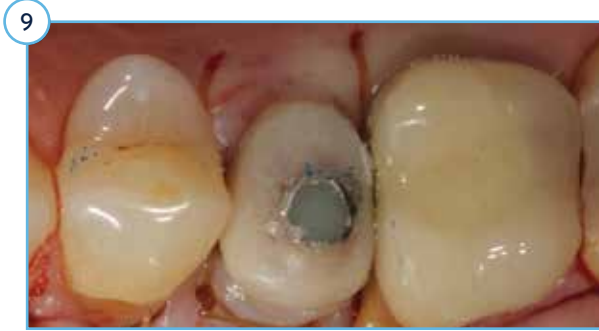Images courtesy of Dr. Suheil Boutros, Grand Blanc, Michigan.



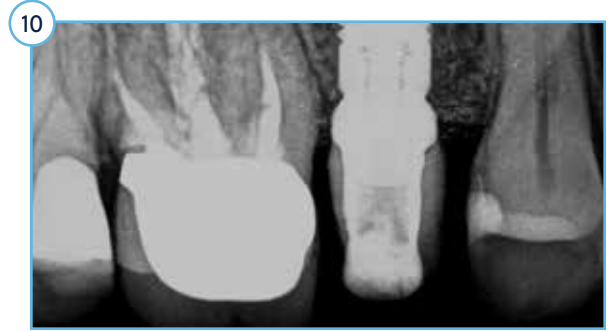7 A 3.7 mmD Trabecular Metal (TM) Implant was placed.



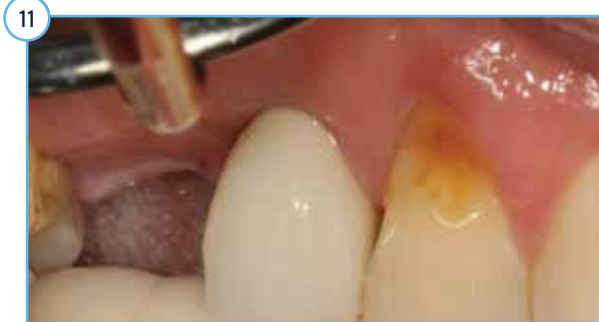8 The TM Implant torqued at 20 Ncm and was deemed stable for immediate provisionalization.



9 The implant was immediately provisionalized with a screw-retained temporary crown out of occlusion.

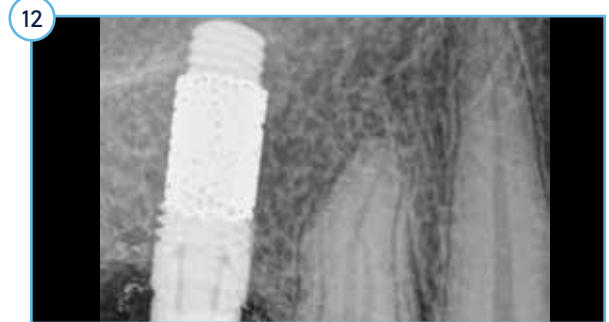


10 Radiograph at time of TM Implant placement and provisionalization.



11 The final crown was placed 10 weeks after implantation. At 36 month follow-up, TM Implant remains in function. (Note the adjacent molar was removed for future implantation).

Images courtesy of Dr. Suheil Boutros, Grand Blanc, Michigan

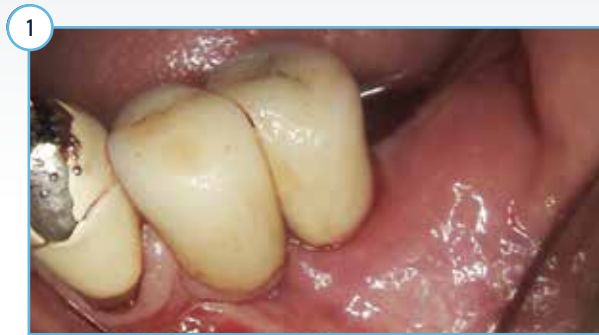

12 Radiograph of TM Implant and stable bone levels after 3 years in function.

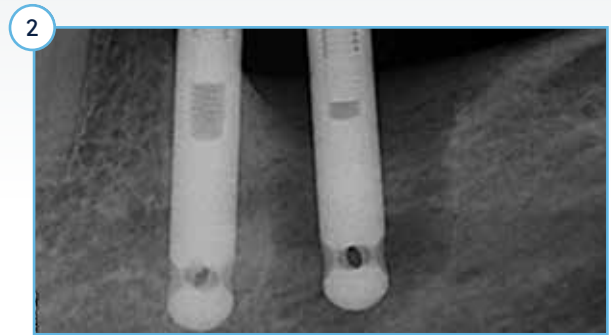Revision Therapy Studies and Cases

Replacement Of Failed Implants

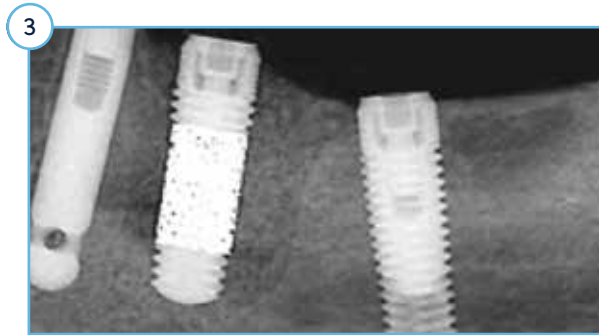Immediate Revision With Puros Allograft-Stabilized Trabecular Metal Implant: 5-Year Follow-Up.



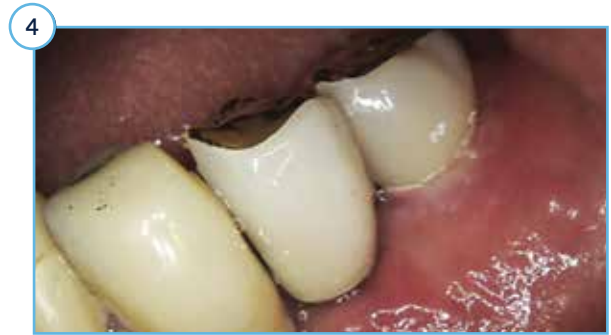1 Peri-implantitis and infection after 12 years in function necessitated implant removal.



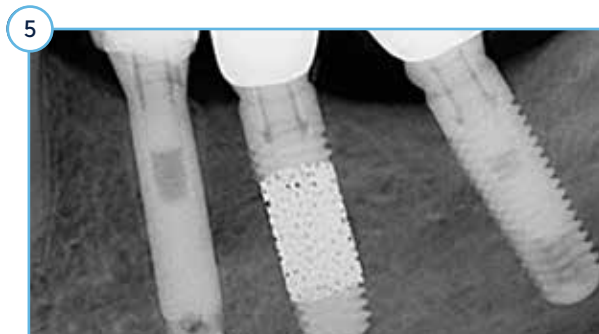2 A very large bone defect is clearly visible circumferentially and apically to the implant.



3 Three months after implantation, Hex-Lock Short Abutments were placed. Radiograph taken prior to completion of abutment seating. The final crown was delivered two weeks later.



4 Healthy soft tissue and an aesthetic result were achieved. After five months of healing, the dramatic increase in ISQ values from 0 to 80 buccally and 82 mesially recorded are evidence of osseointegration.



5 After five years in function, the grafted bone is indistinguishable from the native basal bone and no resorption of the crestal bone is visible.

Images courtesy of Dr. Stefano Bianconi, Bolzano, Italy.

Revision Therapy Studies and Cases

- Agnini, A., Agnini, A., Coachman, C., Digital Dental Revolution. Ch. 4, The Learning Curve; Ch. 6, New Digital Possibilities. Quintessence Pub: 2015.
- Bencharit, S., Byrd, W.C., Altarawneh, S., Hosseini, B., Leong, A., Reside, G., Morelli, T., Offenbacher, S., Development and applications of porous tantalum Trabecular Metal-enhanced titanium dental implants. *Clin Implant Dent Relat Res*, 2014. 16(6): p. 817-26.
- Beuer, F., Schweiger, J., and Güth, J.-F., Digital dentistry meets implantology. The Munich implant concept – a case report. *I & J / Quintessenza Internazionale & JOMI* 2014. 30(2): p. 23-29.
- Bianconi, S., Fontanella, F., and Beccari, R., Perimplant hard and soft tissues modifications in grafted sites. in *European Association of Osseointegration*. 2016. Paris.
- Boutros, M., Trabecular Metal Implants from orthopedics to dental implantology. *Implant Practice*, 2013. 6: p. 1-5.
- Duddeck, D., Maghaireh, H., Faber, F.-J., Neugebauer, J., SEM surface analyses of 120 sterile-packed implants. *EDI Journal / European Journal for Dental Implantologists* 2015. 11(2): p. 64-75.
- Fischer, K. and Fickl, S., Implant therapy with an innovative surface (Trabecular Metal) and CAD/CAM restorations – a clinical case. *I & J / Quintessenza Internazionale & JOMI* 2014. 30(2): p. 51-56.
- Gómez Meda, R., Simultaneous TM Implant placement and horizontal ridge augmentation with IngeniOs HA: a case report. *I & J / Quintessenza Internazionale & JOMI* 2014. 30(2): p. 63-68.
- Karimbux, N., Weber, H.-P., *Clinical Cases in Implant Dentistry*. Ch. 2, Implant Design, Case 3, Special Surfaces (Boutros, S.). Wiley Blackwell: 2017.
- Kim, D.G., Huja, S.S., Tee, B.C., Larsen, P.E., Kenedy, K.S., Chien, H.H., Lee, J.W., Wen, H.B., Bone ingrowth and initial stability of titanium and porous tantalum dental implants: a pilot canine study. *Implant Dent*, 2013. 22(4): p. 399-405.
- Kim, D.G., Jeong, Y.H., Chien, H.H., Agnew, A.M., Lee, J.W., Wen, H.B., Immediate mechanical stability of threaded and porous implant systems. *Clin Biomech (Bristol, Avon)*, 2017. 48: p. 110-117.
- Lee, J.W., Wen, H.B., Battula, S., Akella, R., Collins, M., Romanos, G.E. Outcome after placement of tantalum porous engineered dental implants in fresh extraction sockets: a canine study. *Int J Oral Maxillofac Implants*, 2015. 30(1): p. 134-42.
- Lee, J.W., Wen, H.B., Gubbi, P., Romanos, G.E., New bone formation and trabecular bone microarchitecture of highly porous tantalum compared to titanium implant threads: A pilot canine study. *Clin Oral Implants Res*, 2018. 29(2): p. 164-174.
- Liu, Y., Bao, C., Wismeijer, D., Wu, G., The physicochemical/biological properties of porous tantalum and the potential surface modification techniques to improve its clinical application in dental implantology. *Mater Sci Eng C Mater Biol Appl*, 2015. 49: p. 323-329.
- Ninomiya, J.T., Krolkowski, S.J.A., Hawkins, M., Weihrauch, D. Porous ongrowth surfaces alter osteoblast maturation and mineralization. *J Biomed Mater Res A*, 2015. 103(1): p. 276-81.
- Papi, P., Jamshir, S., Brauner, E., Di Carlo, S., Ceci, A., Piccoli, L., Pompa, G. Clinical evaluation with 18 months follow-up of new PTTM enhanced dental implants in maxillo-facial post-oncological patients. *Ann Stomatol (Roma)*, 2014. 5(4): p. 136-41.
- Peron C and Romanos G, Immediately Loaded Tantalum-based Implants in Infected and Non-infected sites in AADR. 2016: Los Angeles, CA.
- Peron, C., Javed, F., and Romanos, G.E. Crohn's disease and Trabecular Metal Implants: a report of two cases and literature review. *Journal of Osseointegration*, 2015. 7(3).
- Romanos, G.E., Advanced Immediate Functional Loading Requirements for Long-term Success in Modern Implant Dentistry. *Compendium of Continuing Education In Dentistry*, 2014. 35(7): p. 474-483.
- Romanos, G.E., Delgado-Ruiz, R.A., Sacks, D., Calvo-Guirado, J.L., Influence of the implant diameter and bone quality on the primary stability of porous tantalum Trabecular Metal Dental Implants: an in vitro biomechanical study. *Clin Oral Implants Res*, 2018. 29(6): p. 649-655.
- Soardi, C.M., Clozza, E., Zaffe, D., Wang, H.-L., Utilization of Trabecular Metal Implants for the Rehabilitation of a Maxillary Edentulous Arch: A Case Report. *Clinical Advances in Periodontics*, 2014. 4(3): p. 167-174.
- Soardi, C.M., et al., Preliminary outcome in consecutively treated case series with Trabecular Metal Implants. *I & J / Quintessenza Internazionale & JOMI*, 2014. 30(2): p. 91-95.
- Van der Schoor, W.P. and van der Schoor, A.R.M., Surgery all at Once™: Socket preservation and immediate placement of an implant in an infected site in the anterior region – a case report. *I & J / Quintessenza Internazionale & JOMI*, 2014. 30(2): p. 97-102.
- Wang, L., Hu, X., Ma, X., Zhang, Y., Lu, Y., Li, X., Lei, W., Feng, Y., Promotion of osteointegration under diabetic conditions by tantalum coating-based surface modification on 3-dimensional printed porous titanium implants. *Colloids Surf B Biointerfaces*, 2016. 148: p. 440-452.
- Wang, Q., Zhang, H., Li, Q., Ye, L., Gan, H., Liu, Y., Wang, H., Wang, Z. Biocompatibility and osteogenic properties of porous tantalum. *Exp Ther Med*, 2015. 9(3): p. 780-6.

References

1. Schlee, M., van der Schoor, W.P., and van der Schoor, A.R., Immediate loading of Trabecular Metal-enhanced titanium dental implants: interim results from an international proof-of-principle study. *Clin Implant Dent Relat Res*, 2015. 17 (Suppl 1): p. e308-20.
2. Wen, H.B., Schlee, M., van der Schoor, W.P., Mehmke, W.-U., Kamm, T., Beneytout, A., Kottalgi, S., Dinkel, M., and Warner, M., Multicenter Studies of Trabecular Metal Dental Implants: 3-Year Interim Results, in *Academy of Osseointegration*. 2015: San Francisco, CA.
3. Wen, H.B., van der Schoor, W.P., van der Schoor, A.R., and Schlee, M., Immediate Nonocclusal Loading of Trabecular Metal TM-Enhanced Titanium Dental Implants in a Controlled Population: 5-Year Results, in *The 103rd Annual Meeting of American Academy of Periodontology*. 2017: Boston, MA,.
4. Brauner, E., Jamshir, S., Di Carlo, S., Pagnoni, M., Guarino, G., and Pompa, G., Immediate implant loading: a comparison of Trabecular Metal and Tapered Screw-Vent Dental Implants. *OHDM*, 2015. 14(2): p. 1-6.
5. Peron, C. and Romanos, G., Immediate Placement and Occlusal Loading of Single-Tooth Restorations on Partially Threaded, Titanium-Tantalum Combined Dental Implants: 1-Year Results. *Int J Periodontics Restorative Dent*, 2016. 36(3): p. 393-9.
6. Peron, C. and Romanos, G., Immediate Placement and Occlusal Loading of Single-Tooth Restorations on Partially Threaded, Hybrid Dental Implants: 2-Year Results, in *International Symposium of Periodontics and Restorative Dentistry*. 2018: Boston, MA.
7. Peron, C. and Romanos, G., Immediate loading of tantalum-based implants in fresh extraction sockets. Long-term outcomes, in *European Academy of Osseointegration*. 2018: Vienna, Austria.
8. Bencharit, S., Byrd, W.C., and Hosseini, B., Immediate placement of a porous-tantalum, Trabecular Metal-enhanced titanium dental implant with demineralized bone matrix into a socket with deficient buccal bone: a clinical report. *J Prosthet Dent*, 2015. 113(4): p. 262-9.
9. Magic M, Lasic Z, Vlahovic Z, and El Charar E, The influence of implant design on primary implant stability simulating immediate placement conditions of the anterior maxilla. 2015, *Clin Oral Impl Res*.
10. Spinato, S., Zaffe, D., Felice, P., Checchi, L., and Wang, H.L., A Trabecular Metal implant 4 months after placement: clinical-histologic case report. *Implant Dent*, 2014. 23(1): p. 3-7.
11. de Arriba, C.C., Alobera Gracia, M.A., Coelho, P.G., Neiva, R., Tarnow, D.P., Del Canto Pingarron, M., and Aguado-Henche, S., Osseoincorporation of Porous Tantalum Trabecular-Structured Metal: A Histologic and Histomorphometric Study in Humans. *Int J Periodontics Restorative Dent*, 2018. 38(6): p. 879-885.
12. Bencharit, S., Barros, S., Morelli, T., and Offenbacher, S., Biological Effects of Porous Tantalum Trabecular Metal in the Oral Cavity, in *Academy of Osseointegration*. 2016: San Diego, CA.
13. Lee, J.W., Wen, H.B., Gubbi, P., and Romanos, G.E., New bone formation and trabecular bone microarchitecture of highly porous tantalum compared to titanium implant threads: A pilot canine study. *Clin Oral Implants Res*, 2018. 29(2): p. 164-174.
14. Kim, D.G., Jeong, Y.H., Min, K.H., Lee, J.W., and Wen, H.B. Porous Tantalum Increases Interfacial Bone Tissue Mineralization Compared to Titanium Threaded Section of Implants. in *Academy of Osseointegration*. 2016. San Diego, CA.
15. Meirelles, L., Dodo, C., Mendonca, G., Fraser, D., Sartori, E., and Funkenbusch, P., Biomechanical analysis and osteogenic gene expression on porous tantalum implants placed in a gap healing model. *Clin Oral Implants Res*, 2015. 26(Suppl.12).
16. Fraser, D., Mendonca, G., Sartori, E., Funkenbusch, P., Ercoli, C., Meirelles, L. Bone Response to Porous Tantalum Implants In a Gap-Healing Model. *Clin Oral Implants Res*, 2019. 30(2): p. 156-168.
17. Soardi, C.M., Zaffe, D., and Wang, H.-L., Rehabilitation of Extremely Atrophic Maxillae with Mineralized Allograft and Highly Porous Dental Implants in *European Association for Osseointegration*. 2014. Rome, Italy.
18. Edelmann, A. R., Patel, D., Allen, R., Gibson, C.J., Best, A.M., Benharit, S., Retrospective analysis of porous tantalum Trabecular Metal-enhanced titanium dental implants. Accepted for publication in the *Journal of Prosthetic Dentistry*, 2018.
19. Bianconi, S., Bozzoli, P., and Del Fabbro, M., Treatment of Postextraction Sites With Allograft-Stabilized Dental Implants: A Clinical Case Series. *Implant Dent*, 2017. 26(1): p. 37-45.
20. Bianconi, S., Wang, H.-L., Bianconi, L., Del Fabbro, M. Bone modifications around Trabecular Metal Implants inserted without primary stability. A Case Series with 3 years follow up, in *NYU Symposium*. 2019. New York City, New York.
21. Ronda, M. and Stacchi, C., A Novel Approach for the Coronal Advancement of the Buccal Flap. *Int J Periodontics Restorative Dent*, 2015. 35(6): p. 795-801.

22. Schlee, M., Pradies, G., Mehmke, W.U., Beneytout, A., Stamm, M., Meda, R.G., Kamm, T., Poiroux, F., Weinlich, F., del Canto Pingarron, M., Crichton, E., Poulet, J.B., and Bousquet, P., Prospective, Multicenter Evaluation of Trabecular Metal-Enhanced Titanium Dental Implants Placed in Routine Dental Practices: 1-Year Interim Report From the Development Period (2010 to 2011). *Clin Implant Dent Relat Res*, 2015. 17(6): p. 1141-53.
23. Tjaden, A., Schlee, M., van der Schoor, P., van der Schoor, A., Mehmke, W.-U., Kamm, T., Beneytout, A., de Arriba, C.C., Bänninger, L., and H.B., W., Multicenter Studies of Porous Tantalum Trabecular Metal Implants: 4-Year Interim Results, in *Academy of Osseointegration*. 2016: San Diego, CA.
24. Brauner, E., Guarino, G., Jamshir, S., Papi, P., Valentini, V., Pompa, V., and Pompa, G., Evaluation of Highly Porous Dental Implants in Postablative Oral and Maxillofacial Cancer Patients: A Prospective Pilot Clinical Case Series Report. *Implant Dent*, 2015. 24(5): p. 631-7.
25. Peron C and G, R., Immediate Loading of Tantalum-Based Implants in Patients with Systemic Diseases. *Clinical and Radiographic Long-Term Outcomes.*, in *Academy of Osseointegration*. 2017. Orlando, Florida.
26. Peron, C., Javed, F., and Romanos, G.E., Immediate Loading of Tantalum-Based Implants in Fresh Extraction Sockets in Patient With Sjogren Syndrome: A Case Report and Literature Review. *Implant Dent*, 2017. 26(4): p. 634-638.
27. Kim, S.J., Bencharit, S., Morelli, T., Offenbacher, S., and Barros, S.P., Transcriptomic analysis of wound healing around tantalum and titanium in diabetes, in *IADR*. 2017: San Francisco, CA.
28. Hefni, E.K., Bencharit, S., Kim, S.J., Byrd, K.M., Morelli, T., Nociti, F.HI, Offenbacher, S., Barros, S.P. Transcriptomic Profiling of Tantalum Metal Implant Osseointegration in Osteopenic Patients. *British Dental Journal Open*, 2018. 4:17042.
29. Peron C and G, R., Immediate Loading of Trabecular Tantalum-based Implants placed in Infected Sites with Full Ceramic Restorations. 1-year Clinical Evaluation., in *AAID*. 2016. New Orleans, Louisiana
30. El Chaar, E. and Castano, A., A Retrospective Survival Study of Trabecular Tantalum Implants Immediately Placed in Posterior Extraction Sockets Using a Flapless Technique. *J Oral Implantol*, 2017. 43(2): p. 114-124.
31. Battula, S., Lee, J.W., Wen, H.B., Papanicolaou, S., Collins, M., and Romanos, G.E., Evaluation of Different Implant Designs in a Ligature-Induced Peri-implantitis Model: A Canine Study. *Int J Oral Maxillofac Implants*, 2015. 30(3): p. 534-45.
32. Dimaira, M. Immediate Placement of Trabecular Implants in Sites of Failed Implants. *Int J. Oral Maxillofac Implants*, 2019. 34(5): p. e77–e83.
33. Boby, J., UHMWPE: the good, bad, & ugly. Fixation and bearing surfaces for the next millennium. *Orthop*, 1999. 22(9): p. 810-812.
34. Cohen, R., A porous tantalum Trabecular Metal: basic science. *Am J Orthop (Belle Mead NJ)*, 2002. 31(4): p. 216-7.
35. Nasser, S. and Poggie, R.A., Revision and salvage patellar arthroplasty using a porous tantalum implant. *J Arthroplasty*, 2004. 19(5): p. 562-72.
36. Unger, A.S., Lewis, R.J., and Gruen, T., Evaluation of a porous tantalum uncemented acetabular cup in revision total hip arthroplasty: clinical and radiological results of 60 hips. *J Arthroplasty*, 2005. 20(8): p. 1002-9.
37. Wigfield, C., Robertson, J., Gill, S., and Nelson, R., Clinical experience with porous tantalum cervical interbody implants in a prospective randomized controlled trial. *Br J Neurosurg*, 2003. 17(5): p. 418-25.

For more information, visit [ZimVie.com](https://www.zimvie.com)

ZimVie
4555 Riverside Drive
Palm Beach Gardens, FL 33410
1-800-342-5454
Phone: +1-561-776-6700
Fax: +1-561-776-1272
dentalCS@ZimVie.com



Unless otherwise indicated, as referenced herein, all trademarks and intellectual property rights are the property of ZimVie Inc. or an affiliate; and all products are manufactured by one or more of the dental subsidiaries of ZimVie Inc. (Biomet 3i, LLC, Zimmer Dental, Inc., etc.) and marketed and distributed by ZimVie Dental and its authorized marketing partners. For additional product information, please refer to the individual product labelling or instructions for use. Product clearance and availability may be limited to certain countries/regions. This material is intended for clinicians only and does not comprise medical advice or recommendations. Distribution to any other recipient is prohibited. This material may not be copied or reprinted without the express written consent of ZimVie. ZV0912 REV A 10/23 ©2023 ZimVie. All rights reserved.

